

---

## Keratorefractive lenticule extraction in eyes with post-herpetic scars

**Antonio Leccisotti,<sup>1,2</sup> Stefania V. Fields,<sup>1</sup> Giuseppe De Bartolo,<sup>1</sup> Christian Crudale,<sup>1</sup>  
Matteo Posarelli<sup>1,3</sup>**

<sup>1</sup>*Siena Eye Laser, Poggibonsi, Siena, Italy;* <sup>2</sup>*School of Biomedical Sciences, Ulster University, Coleraine, United Kingdom;*  
<sup>3</sup>*Liverpool University, United Kingdom*

### ABSTRACT

Correcting refractive errors by remodeling the corneal curvature with an excimer laser (which emits ultraviolet radiation) may reactivate a latent Herpes Simplex Virus (HSV), resulting in keratitis. New techniques using infrared sources, such as femtosecond-assisted Keratorefractive Lenticule Extraction (KLEx), may thus provide a safer approach to eyes with previous HSV keratitis; however, no cases of KLEx in such cases have been reported. As a result, we present three cases in which KLEx successfully corrected myopia. Three myopic eyes from three patients with a known history of healed HSV keratitis that occurred more than 12 months before surgery underwent KLEx. All patients received oral antiviral prophylaxis before and after surgery. In case 1, the post-HSV scar was semiperipheral, involving only a portion of the treated area; surgery went smoothly, with the intrastromal lenticule well delineated and dissected even through the scar. In cases 2 and 3, the healed scar was peripheral and did not interfere with surgery. After 6 months, all three cases had good visual acuity without complications. Finally, KLEx combined with antiviral prophylaxis can effectively correct myopia in eyes with healed HSV. The femtosecond laser can penetrate non-dense, peripheral corneal scars.

**Key words:** Keratorefractive Lenticule Extraction (KLEx), myopia, herpes simplex virus, keratitis.

---

#### Corresponding author:

Antonio Leccisotti, Siena Eye Laser, Largo Usilia 31, 53036 Poggibonsi (Siena), Italy.  
E-mail: leccisotti@libero.it

Received: 18 March 2024.  
Accepted: 2 June 2024.

*Laser Therapy*  
©Copyright: the Author(s), 2024  
Licensee PAGEPress, Italy  
Laser Therapy 2024; 31:397  
doi:10.4081/ljt.2024.397

The correction of refractive errors by corneal excimer laser procedures (laser in situ keratomileusis, LASIK, and photorefractive keratectomy, PRK) poses the risk of reactivating latent Herpes Simplex Virus (HSV) in eyes with or without a previous HSV keratitis.<sup>1</sup> The possible causes of reactivation are epithelial removal (as in PRK and partially in LASIK), the ultraviolet light of excimer laser, and the postoperative use of topical corticosteroids.<sup>2,3</sup>

Keratorefractive corneal lenticule extraction (recently abbreviated as KLEx)<sup>4</sup> uses a femtosecond (infrared) laser to correct myopia and myopic astigmatism by removing an intrastromal disc of tissue through a small incision.<sup>5</sup> In KLEx, the avoidance of an ultraviolet source and the minimal epithelial disruption may present an advantage in preventing HSV reactivation; on the other hand, the need for a transparent cornea for the intrastromal laser procedure prevents its use in the presence of HSV scars in the optical zone.

Only 1 case of herpetic keratitis after KLEx has been reported, in a patient with no history of HSV infection,<sup>6</sup> but studies of KLEx in eyes with healed HSV keratitis are completely lacking. We therefore report 3 cases of KLEx performed in eyes with post-HSV peripheral corneal scars with antiviral prophylaxis, to assess the efficacy and safety of the treatment.

## Materials and Methods

A retrospective analysis of patients undergone KLEx following HSV keratitis was done. The Institutional Review Board provided approval on January 10<sup>th</sup>, 2024. The research followed the tenets of the Declaration of Helsinki; patients provided a signed informed consent. Previous HSV infection was confirmed by clinical records reporting a typical dendritic or stromal lesion. Three eyes of 3 patients were finally identified.

The inclusion criteria for surgery were: i) myopia or compound myopic astigmatism with spherical equivalent (SE) -1 to -12 diopters (D), with at least 18 months of refractive stability, and refractive astigmatism  $\leq 3$  D; ii) age: between 25 and 50 years; iii) general health status: absence of collagen vascular disease, no pregnancy; iv) ocular disease: no previous surgery; absence of macular or lens abnormality; no topical treatment for ocular hypertension; absence of dry eye symptoms, non-invasive tear film break-up time  $\geq 10$  seconds (MS-39, Costruzione Strumenti Oftalmici), lacrimal fluid osmolarity  $\leq 300$  mOsm/l

(I-PEN, Imedpharma); in the case of previous stromal infection, absence of corneal scars in the optical zone, with last recurrence earlier than 12 months before surgery; vii) corneal features on OCT and Placido topography (MS-39): central pachymetry  $\geq 480$   $\mu\text{m}$ ; regular posterior elevation, anterior and posterior tangential topography; no signs of ectasia; viii) Corrected Distance Visual Acuity (CDVA)  $\geq 20/40$  Snellen; ix) minimum follow-up: 6 months from treatment.

The pre-operative assessment consisted of Uncorrected Distance Visual Acuity (UDVA), CDVA, manifest and cycloplegic refraction (by tropicamide eye drops), undilated and dilated slit-lamp evaluation, Placido corneal topography, OCT tomography with epithelial and stromal thickness evaluation, computer-assisted scotopic pupillography, tonometry, tear function evaluation.

Soft contact lens use was interrupted 1 month before examination and surgery; rigid contact lens use was interrupted 3 months before examination and surgery. All patients were informed about the surgical procedure and provided written consent.

## *Surgical technique of KLEx*

Our technique for KLEx with the CLEAR application has been published.<sup>7</sup>

Briefly, full manifest spherical and cylindrical corrections were planned. The thickness of the cap (cornea anterior to the upper lenticule interface) was set at 120  $\mu\text{m}$ . A single super-temporal 2.5 mm incision was programmed. Femtosecond laser power and velocity were adjusted to obtain a uniform pattern of tiny, non-confluent plasma bubbles.

After topical anesthesia with oxybuprocaine, a drop of unpreserved 0.2% sodium hyaluronate was dripped on the cornea. The Ziemer Z8 handpiece was docked, and the patient was instructed to look into the red fixation light within the handpiece, suction was activated, and centration was accomplished.

Once lenticule delineation was completed, the super-temporal incision was scored and the lenticule separated with a Reinstein Lenticule Separator (Malosa MMSU1297S). Straight, fine-tip tying forceps (Malosa MMSU1414CS) were used to extract the lenticule.

Topical post-operative treatment consisted of dexamethasone 0.1% and netilmicin 0.3% eyedrops 5 times daily for 5 days and then 3 times daily for 5 days, and unpreserved 0.2% sodium hyaluronate as lubricant as needed.

Oral acyclovir (400 mg twice a day) was started on the day before surgery and continued for 2 weeks.

## Case reports

### Case 1 (male, 22 years old, OD)


The patient, following HSV epithelial keratitis in OD 2 years previously, had developed a semi-peripheral corneal opacity (Figure 1). Corneal tomography was regular, except for a change in curvature over the corneal scar; central corneal pachymetry on OCT was 563  $\mu\text{m}$  (Figure 2). Refraction in (in diopters) in OD was  $-3 - 1 \times 132^\circ$ , and CDVA was 20/20. KLEx was performed with a 125- $\mu\text{m}$  cap and a 6.9-mm optical zone.

Surgery was uneventful, with a good delineation of the lenticule and an area of opaque bubble layer (OBL) over the lesion, extending to the limbus (Figure 3A). Dissection was normal, with no areas of undue resistance (Figure 3 B and C), and an intact lenticule was finally extracted (Figure 3 D).

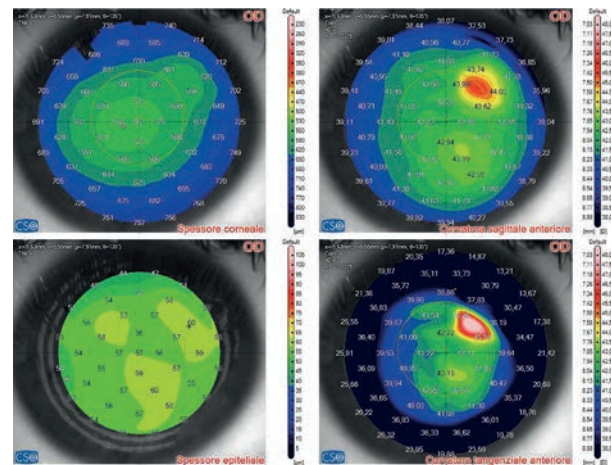
The next day, in OD the cornea was transparent, UCVA was 20/20, refraction  $+0.25 +0.50 \times 164^\circ$  (Figures 4 and 5). At 6 months no complications were observed, UCVA was 20/20, refraction  $+0.50 \times 150^\circ$ .

### Case 2 (male, 34 years old, OS)

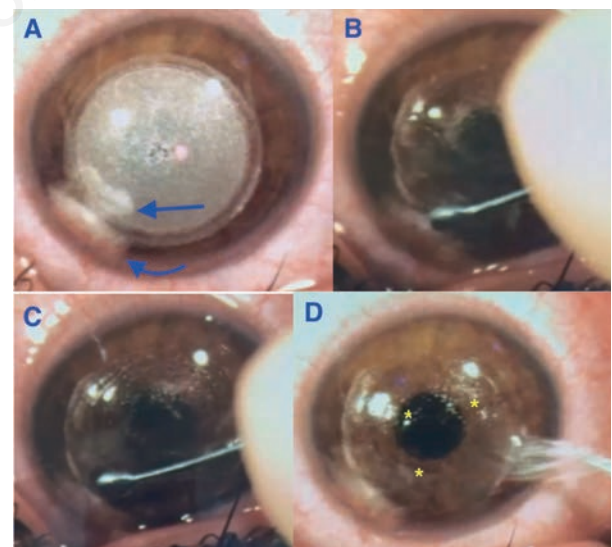
The patient, following 2 episodes of HSV stromal keratitis in OS 5 and 4 years previously, presented with a temporal peripheral stromal opacity, not involving the optical zone. Corneal tomography was regular; central corneal pachymetry on OCT was 529  $\mu\text{m}$ . Refraction in OD was  $-6.25 - 0.5 \times 2^\circ$ , and CDVA was 20/20. KLEx was performed with a 120- $\mu\text{m}$  cap and a 6.5-mm optical zone.




**Figure 1.** Case 1. The pre-operative corneal section at optical coherence tomography (OCT) shows the stromal opacity as a semiperipheral subepithelial gray area, indicated by the arrow.



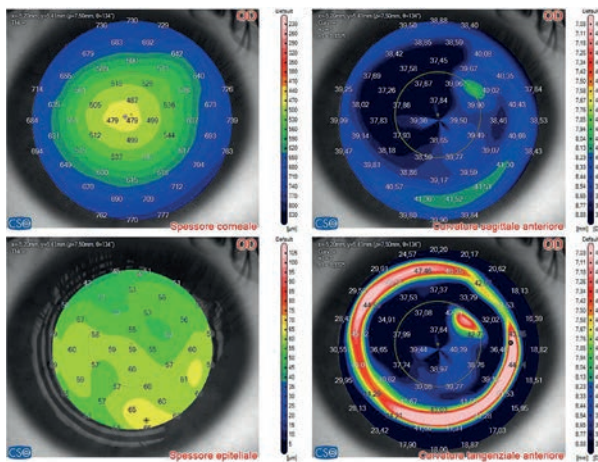
**Figure 2.** Case 1. Corneal tomography by optical coherence tomography (OCT). Top left: total corneal thickness in micron. Top right: anterior curvature with sagittal algorithm, showing a more curved area overlying the scar. Bottom left: corneal epithelial thickness in micron. Bottom right: anterior curvature with a tangential algorithm, showing a more curved area overlying the scar.



**Figure 3.** Case 1 (surgeon view): phases of keratorefractive lenticule extraction. A) after the femtosecond delineation, a uniform bubble pattern is evident. The scarred area (straight arrow) is characterized by plasma accumulation, extending peripherally into a limbal opacity (curved arrow); B) manual dissection of the anterior interface by a spatula; C) manual dissection of the posterior interface; D) extraction of the corneal lenticule by forceps through the access incision. The asterisks indicate the intact lenticule edges.



**Figure 4.** Case 1. Post-operative (day 1) corneal section at optical coherence tomography (OCT): the stromal opacity is indicated by the arrow. The asterisks delineate the surgical interface.



**Figure 5.** Case 1. Corneal tomography by optical coherence tomography (OCT) after keratorefractive lenticule extraction. Top left: total corneal thickness in micron, showing the remodeled corneal shape. Top right: anterior curvature with a sagittal algorithm, partially showing a more curved area overlying the scar and evidencing the post-operative flattening. Bottom left: corneal epithelial thickness in micron. Bottom right: anterior curvature with a tangential algorithm, showing a more curved area overlying the scar and the red ring of the curvature gradient, indicating the edge of the treatment. Good centration and a large optical zone are evident.

Surgery was uneventful, and an intact lenticule was finally extracted.

The next day, in OD the cornea was transparent, UCVA was 20/20-, refraction +0.25 +0.75 x 95°.

At 6 months no complications were observed, UCVA was 20/20, refraction +0.50 x 83°.

### Case 3 (female, 40 years old, OS)

The patient, following 2 episodes of HSV epithelial keratitis in OS 7 and 6 years previously, presented with an in-

ferior peripheral corneal opacity, not involving the optical zone. Corneal topography was regular, with a central pachymetry of 542 µm. Refraction in OS was -5.37 - 0.25 x 47°, and CDVA was 20/20. KLEx was performed with a 120-µm cap and a 6.5-mm optical zone.

Surgery was uneventful, and an intact lenticule was finally extracted.

The next day, in OS the cornea was transparent, UCVA was 20/20, refraction +0.5.

At 6 months no complications were observed, UCVA was 20/20, refraction -0.25 x 162°.

## Discussion

In our 3 cases, KLEx was performed uneventfully, achieving good refractive results and without HSV recurrence. In case 1, the scar was partially occupying the optical zone, but the lenticule was well delineated and separated without resistance.

In animal experimental models, corneal epithelial scraping followed by excimer ablation leads to HSV reactivation in 45% of cases.<sup>8</sup> Clinically, HSV keratitis has been observed after both LASIK, where an excimer laser is used and the epithelium is circularly disrupted by the creation of the flap,<sup>9-12</sup> and after PRK, where a large epithelial defect is created before excimer laser ablation.<sup>13,14</sup> Two-thirds of the cases of post-excimer laser herpetic keratitis have a previous history of HSV ocular infection;<sup>1</sup> in such situations, oral antiviral prophylaxis has shown a protective effect against reactivation.<sup>15,16</sup> When not reactivated, latent corneal HSV (identified in 5% of extracted lenticules) does not affect the safety and results of KLEx.<sup>17</sup>

It is normally assumed that KLEx should be avoided in the presence of scars in the zone to be treated, as femtosecond laser cannot penetrate opaque tissues.<sup>18</sup> In our case 1, the opaque area was successfully delineated and dissected. The capability of the laser to penetrate semi-opaque tissue is dependent on the uniformity of the delivered energy, precise focusing, and on-the-spot pattern. The Ziemer platform is characterized by low energy and confluent spots, delivered from a close source,<sup>18</sup> which may explain the relative ability to penetrate nondense scars.

The limitations of this study are the limited case series and the lack of a control group; these conditions were however not easy to fulfill because of the relative rarity of the pathology and for ethical reasons.

## Conclusions

The treatment of refractive errors by KLEx in 3 eyes with post-herpetic scars not occupying the visual axis produced good visual results, with no complications. A semi-peripheral scar was successfully delineated and dissected.

## Funding

No funding was obtained.

## Conflict of interest

The authors have no financial or proprietary interest in any product or technique mentioned. The authors declare no potential conflict of interest, and all authors confirm accuracy.

## Contributions

AL and SVF contributed to the conception, drafting, final approval, and agreement to be accountable for all aspects of the work. GDB and MP contributed to the analysis of data, revising, final approval, and agreement to be accountable for all aspects of the work. CC contributed to the conception, analysis of data, final approval, and agreement to be accountable for all aspects of the work.

## Ethics approval

The study has been granted an exemption from requiring ethics approval by the Institutional Review Board at Siena Eye Laser. Ethical approval is not required for this study in accordance with national guidelines.

## Informed consent

All patients participating in this study signed a written informed consent form for participating in this study.

## Patient consent for publication

Written informed consent was obtained from a legally authorized representative(s) for anonymized patient information to be published in this article.

## Availability of data and materials

All data generated or analyzed during this study are included in this published article.

## References

1. Moshirfar M, Milner DC, Baker PA, et al. Corneal refractive surgery in patients with a history of herpes simplex keratitis: a narrative review. *Clin Ophthalmol* 2020;14:3891–3901
2. Pepose JS, Laycock KA, Miller JK, et al. Reactivation of latent herpes simplex virus by excimer laser photokeratectomy. *Am J Ophthalmol* 1992;114:45–50.
3. Asbell PA. Valacyclovir for the prevention of recurrent herpes simplex virus eye disease after excimer laser photokeratectomy. *Trans Am Ophthalmol Soc.* 2000;98:285–303.
4. Dupps WJ Jr, Randleman JB, Kohnen T, et al. Scientific nomenclature for keratorefractive lenticule extraction (KLEx) procedures: a joint editorial statement. *J Cataract Refract Surg* 2023;49:1085.
5. Sekundo W, Kunert KS, Blum M. Small incision corneal refractive surgery using the small incision lenticule extraction (SMILE) procedure for the correction of myopia and myopic astigmatism: results of a 6 month prospective study. *Br J Ophthalmol* 2011;95:335–9.
6. Ramirez-Miranda A, Mangwani-Mordani S, Quiroz-Casian N, et al. Combined bacterial and Herpes Simplex Virus keratitis following small-incision lenticule extraction for the correction of myopia. *Case Rep Ophthalmol* 2021;12:227–31.
7. Leccisotti A, Fields SV, De Bartolo G. Refractive corneal lenticule extraction with the CLEAR femtosecond laser application. *Cornea* 2023;42:1247–56.
8. Dhaliwal DK, Barnhorst DA, Romanowski E, et al. Efficient reactivation of latent herpes simplex virus type 1 infection by excimer laser keratectomy in the experimental rabbit ocular model. *Am J Ophthalmol* 1998;125:488–92.
9. Moshirfar M, Welling JD, Feiz V, et al. Infectious and noninfectious keratitis after laser in situ keratomileus occurrence, management, and visual outcomes. *J Cataract Refract Surg* 2007;33:474–83.
10. Davidorf JM. Herpes simplex keratitis after LASIK. *J Refract Surg* 1998;14:667.
11. Kamburoglu G, Ertan A. Peripheral herpes simplex keratitis following LASIK. *J Refract Surg* 2007;23:742–743.
12. Levy J, Lapid-Gortzak R, Klemperer I, Lifshitz T. Herpes simplex virus keratitis after laser in situ keratomileus. *J Refract Surg* 2005; 21:400–2.
13. Nagy ZZ, Keleman E, Kovacs A. Herpes simplex keratitis after photorefractive keratectomy. *J Cataract Refract Surg* 2003;29:222–3.
14. Wulff K, Fechner PU. Herpes simplex keratitis after photorefractive keratectomy. *J Refract Surg* 1997;13:613.
15. Jarade EF, Tabbara KF. Laser in situ keratomileus in eyes with inactive herpetic keratitis. *Am J Ophthalmol* 2001;132:779–80.
16. De Rojas Silva MV, Díez-Feijóo E, Javaloy J, Sánchez-Salorio M. Prophylactic perioperative antiviral therapy for LASIK in patients with inactive herpetic keratitis. *J Refract Surg* 2006;22:404–6.
17. Liu M, Song W, Gao W, et al. Impact of latent virus infection in the cornea on corneal healing after small incision lenticule extraction. *Microorganisms* 2023;11:2441.
18. Vryghem JC, Devogelaere T, Stodulka P. Efficacy, safety, and flap dimensions of a new femtosecond laser for laser in situ keratomileus. *J Cataract Refract Surg* 2010;36:442–8.