
Use of laser for uncovering a mandibular retained tooth: case report

Huichao Wang,¹ Yupu Li,¹ Ting Zhao,¹ Ruonan Sun,¹ Jean-Paul Rocca,^{1,2} Carlo Fornaini^{1,2}

¹Department of Stomatology, 2nd Shijiazhuang Second Hospital, Hebei Province, China; ²Micoralis Laboratory EA7354, Faculty of Dentistry, University of Nice Sophia Antipolis, Nice, France

ABSTRACT

This clinical study aimed to describe a case of lower impacted canine to demonstrate the advantages of diode laser for crown exposure during orthodontic treatment. The patient received a surgical intervention by an infra-red diode laser to uncover a retained lower canine. The intervention did not need anesthetic injection and suture apposition, the patient did not refer pain, and the healing process was completed after a week. The diode laser was safe, fast, and easy to use, and the avoidance of bleeding was reached due to its excellent absorption by hemoglobin: this is particularly important considering that, for obtaining a strong adhesion, a bracket must be bonded in a dry enamel surface. The use of an infrared diode laser is a proper approach in the surgery of retained teeth during orthodontic treatment.

Key words: diode laser; orthodontics; retained teeth; oral surgery.

Corresponding author:

Carlo Fornaini, Micoralis Laboratory EA7354, Faculty of Dentistry, University of Nice Sophia Antipolis,
24 Avenue des Diabls Bleus, 06357 Nice, France.
E-mail: carlo@fornainident.it

Received: 1 December 2023.
Accepted: 4 December 2023.

Introduction

Managing impacted teeth represents an example of strict cooperation between orthodontists and oral surgeons: only by a treatment plan discussed and approved by both clinicians will it be possible to reach a successful result.

An impacted tooth is a tooth that fails to erupt into the dental arch within a specific time.¹ Teeth frequently impacted are third molars, maxillary canines, maxillary and mandibular premolars, and maxillary central incisors; the prevalence of impacted maxillary canines is 0.9–2.2%, and of impacted mandibular canines is 0.05–0.4%.^{2,3} Failure of eruption of the mandibular canine is not usual and is most often caused by local factors such as mechanical obstruction (supernumerary tooth/cyst/tumor), insufficient space in the dental arch, and tooth-arch size discrepancy. Systemic factors such as genetic disorders, endocrine deficiencies, and previous irradiation of the jaws also have been suggested to play a role.⁴

The periodontal outcome of surgically exposed and orthodontically extruded impacted teeth compared with the spontaneously erupted contralateral teeth indicates that orthodontic extrusion of impacted front teeth does not jeopardize their periodontal health, and this procedure appears to be a satisfactory alternative to extraction and transplantation.⁵

Even if the most popular approach to the surgical treatment of ectopic canines consists of closed-flap forced eruption, whereby the gingival flap is sutured back over the canine after exposure and bracketing, there is also the possibility of an open exposure to create an epithelialized fenestration or window through the gingiva that leaves the canine visible.⁶ The main advantage of this technique is related to the opportunity, if the bracket accidentally detaches from the tooth, to avoid an additional intervention for re-bonding it, and laser technology may be considered the best approach in this kind of intervention.⁷

Laser utilization has been used for many years in oral surgery, offering several advantages when compared to the conventional approach, such as the possibility of reducing or avoiding the use of anesthetics, which is especially important in pediatric patients, the bloodless surgical field with consequent suture no-need, and postoperative pain and discomfort reduction.^{8,9} The so-called “photobiomodulation,” as well as the antimicrobial power of laser energy, can enhance the healing process.¹⁰⁻¹²

The diode laser has become very popular in dentistry due to its reduced cost and size and its delivery system

consisting of optical fiber, which is simple to use and ergonomic.¹³

Laser-assisted minimally invasive surgery of retained teeth is faster and easier to perform, also in difficult anatomical situations.¹⁴

This clinical study aimed to describe a clinical case of lower impacted canine to demonstrate the advantages of diode laser for crown exposure during orthodontic treatment.

Case Report

T S, a 28 year old man, came to our clinics to receive an orthodontics treatment to make the teeth alignment of the upper arch and to close a space between the central incisor (lateral was missing) and the premolar in the right side of the mandibular arch.

At the radiographic examination, it was noticed the presence of a retained canine that made difficult the space closure: it was suggested the patient perform a surgical-orthodontic treatment to uncover the retained tooth as well as insert it into the mandibular arch.

A fixed orthodontic appliance was put in the upper and lower arches, and a coil spring was inserted to open the space between the right lower lateral incisor and premolar (Figure 1, 2).

With the help of intraoral radiographs, it was established that the canine was only covered by mucosa on the lingual side: for this reason, it was decided for a laser-assisted intervention.

The patient was instructed on the details and possible risks of this kind of intervention, and after his approval, informed consent was signed.

A diode laser (808 nm, LaseMAr 800, Eufoton, Italy)

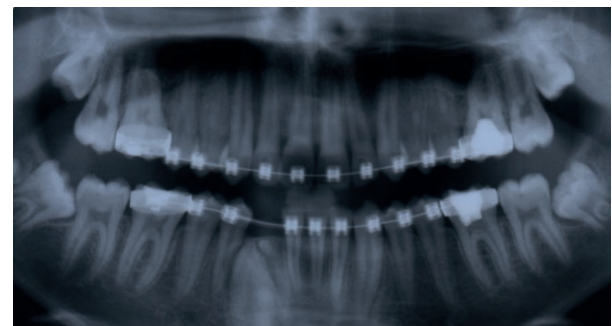


Figure 1. Pre-intervention radiograph.

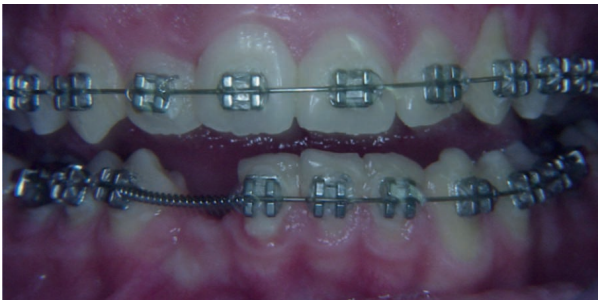

Figure 2. Coil-spring inserted into the wire arch to open the space.

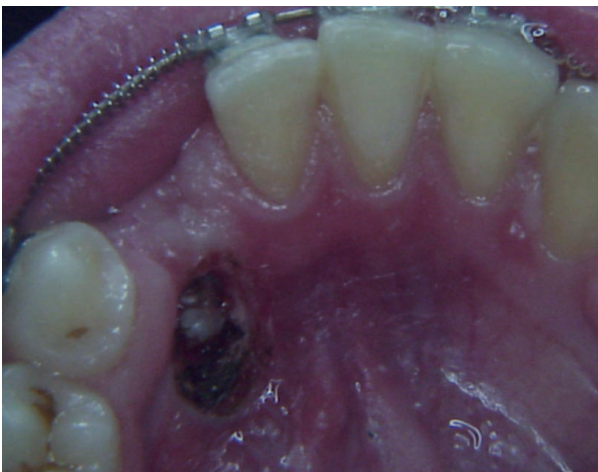

Figure 3. Just after intervention: no bleeding is present.

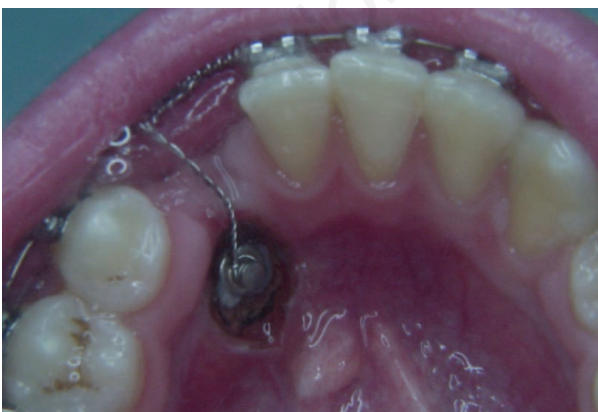

Figure 4. A bracket is bonded after the intervention, and a metallic ligature is applied for elastic traction insertion.

was utilized with a 320 μm diameter optical fiber at 3W CW output power.

The intervention had a 175 sec. duration, only topical anesthetics (EM) were applied, and the suture was not put.

All the laser safety procedures were observed: the patient, operator, and assistant wore protective glasses specific to the wavelength utilized. Just after the intervention, due to the bleeding absence, a bracket was bonded and connected to the wire arch; a week later, it was started to get traction using an elastic ligature (Figure 3, 4).

The patient reported pain absence during and after the procedure.

Three months later, the canine crown was exposed, and it was possible to bond a bracket in the vestibular side and insert it into a nickel-titanium wire (Figure 5).

Five months later, the arch alignment was obtained, and two months after debonding was performed, considering the excellent health of periodontal tissues (Figure 6).

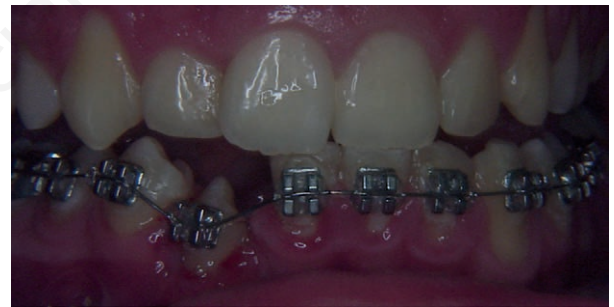

Figure 5. Once the crown is exposed, a bracket is bonded on the vestibular side and inserted into a Ni-Ti arch.

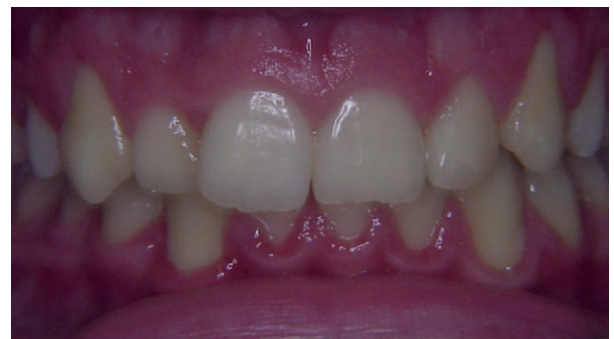

Figure 6. After debonding.

Discussion

One of the main goals of modern dentistry and oral surgery is represented by “minimal invasiveness,” which consists of size intervention area, pain, and discomfort minimizing even by the integration of conventional treatments with the new technologies and laser demonstrated being able to play an essential role in this kind of situations.¹⁵

Earlier studies conducted by several authors demonstrated that traditional surgery is more invasive and challenging to perform. In contrast, the laser is safe, minimally invasive, bactericidal, and provides a bloodless operating field.¹⁶

Different laser wavelengths have been proposed for oral surgery: CO₂ laser,¹⁷ Nd:YAG laser,¹⁸ Er:YAG,¹⁹ Er,Cr:YSGG²⁰ lasers, and diode²¹ lasers.

While CO₂ and Nd:YAG lasers were not considered due to their significant thermal elevation with possible risks for pulp vitality, Erbium family lasers were rejected because they could not get an effective bleeding control.

Our choice to use this last was determined because of its safe and easy use and the avoidance of bleeding due to its excellent absorption by hemoglobin: this is particularly important considering that, for obtaining a strong adhesion, a bracket may be bonded in a dry enamel surface.

Moreover, with the parameters utilized, thermal elevation in the tissue was limited, allowing a faster and painless healing process, also thanks to the opportunity to avoid sutures.

Lastly, the utilization of optic fiber in contact mode made it easier not too difficult to perform the intervention in the lingual mandibular side which is an area not so easy to reach.²²

Conclusions

The use of an infrared diode laser seems to be a proper approach in the surgery of retained teeth during orthodontic treatment.

Contributions: LY, ZT, and SR performed the orthodontic treatment, WH made the surgical intervention, CF and JPR wrote the manuscript,

Conflict of interest: the authors declare no potential conflict of interest, and all authors confirm accuracy.

Ethics approval and consent to participate: no ethical committee approval was required for this case report by the Department because this article does not contain any studies with human participants or animals. Informed consent was obtained from the patients included in this study.

Patient consent for publication: the patient gave his written consent to use his data for the publication of this case report and any accompanying images.

Availability of data and materials: all data underlying the findings are fully available.

References

1. Park JH, Srisurapol T, Tai K. Impacted maxillary canines: diagnosis and management. *Dent Today* 2012;31:62 64–6; quiz 68–9.
2. Rohrer A. Displaced and impacted canines. *Int J Orthod Oral Surg* 1929;15:1003.
3. Taguchi Y, Kurol J, Kobayashi H, et al. Eruption disturbances of mandibular permanent canines in Japanese children. *Int J Paediatr Dent* 2001;11:98–102.
4. Counihan K, Al-Awadhi EA, Butler J. Guidelines for the assessment of the impacted maxillary canine. *Dent Update* 2013;40:770–2, 775–7.
5. Quirynen M, Op Heij DG, Adriansen A, et al. Periodontal health of orthodontically extruded teeth. A split-mouth, long-term clinical evaluation. *J Periodontol* 2000;71:1708–14.
6. Sherwood K. Evidence-based surgical-orthodontic management of impacted teeth. *Atlas Oral Maxillofac Surg Clin North Am* 2013;21:199–210.
7. Fornaini C, Rocca JB, Bertrand MF, et al. Nd:YAG and diode laser in the surgical management of soft tissues related to orthodontic treatment. *Photomed Laser Surg* 2007;25:381–92.
8. Parkins FM, Miller RL, Furnish GM, O’Toole TJ. A preliminary report: YAG laser treatment in pediatric dentistry. *J Calif Dent Assoc* 1991;19:43–44, 46–48, 50.
9. Dederich DN. Lasers in dentistry. *J Am Dent Assoc* 1991;122:10–1.
10. Cobb CM, McCawley TK, Killoy WJ. A preliminary study on the effects of the Nd:YAG laser on root surfaces and subgingival microflora in vivo. *J Periodontol* 1992;63:701–707.
11. Moritz A, Schoop U, Goharkhay K, et al. Treatment of periodontal pockets with a diode laser. *Lasers Surg Med* 1998;22:302–11.
12. Schoop U, Kluger W, Moritz A, et al. Bactericidal effect of different laser systems in the deep layers of dentin. *Lasers Surg Med* 2004;35:111–6.
13. Fornaini C, Merigo E, Sozzi M, et al. Four different diode lasers comparison on soft tissues surgery: a preliminary ex vivo study. *Laser Ther* 2016;25:105–114.

14. Balasupramaniam MT, Anitha A, Manovijay B, Ravi S. Various surgical methods of impacted maxillary canine exposure: A case series. *J Indian Soc Periodontol* 2023;27:212-5.
15. Silva AS, Nunes AMM, Neves PAM, Lago ADN. Use of high-power lasers in pediatric dental surgeries: case reports. *Gen Dent* 2022;70:56-59.
16. Cherian D, Saeed R, Anusha K, et al. Management of ankyloglossia by functional frenuloplasty using diode laser. *J Orthod Sci* 2023;12:23.
17. Asnaashari M, Behnam Roudsari M, Shirmardi MS. Evaluation of the Effectiveness of the Carbon Dioxide (CO₂) Laser in Minor Oral Surgery: A Systematic Review. *J Lasers Med Sci* 2023;14:e44.
18. Vescovi P, Corcione L, Meleti M, et al. Nd:YAG laser versus traditional scalpel. A preliminary histological analysis of specimens from the human oral mucosa. *Lasers Med Sci* 2010;25:685-91.
19. Ou M, Huang X. Histological evaluation of mouse tongue incisions after Er:YAG laser surgery with different pulse energies versus after conventional scalpel surgery. *Lasers Med Sci* 2023;38:181.
20. Liu Y, Peng Q, Liu B, et al. Er,Cr:YSGG Laser Therapy for Drug-Induced Gingival Overgrowth: A Report of Two Case Series. *Front Surg* 2022;9:922649.
21. Maboudi A, Fekrazad R, Shiva A, et al. Gingivectomy with Diode Laser Versus the Conventional Scalpel Surgery and Non-surgical Periodontal Therapy in Treatment of Orthodontic Treatment-Induced Gingival Enlargement: A Systematic Review. *Photobiomodul Photomed Laser Surg* 2023;41:449-459.
22. Fornaini C. Different laser wavelengths in the orthodontic surgery of the retained teeth. *Laser Ther.* 2012;21:47-50.

Non-commercial use only