

Management interventions for amputation stump neuromas: evidence based review and cost-benefit analysis

Ernest A. Azzopardi,¹⁻⁵ Philipa Stewart,⁶ Dean Edward Boyce,⁷ Maxwell Murison,¹
Hazim Sadideen,⁸ Matteo Tretti Clementoni⁹

¹Welsb Laser Service, Neath Port Talbot Hospital, Neath, Wales, United Kingdom; ²Skinsurgeon@ELms Clinic, Triq il Pirinej, Malta; ³Consultant Surgeon in Private Practice, The London Welbeck Hospital, Marylebone, London, United Kingdom; ⁴Department of Anatomy, Faculty of Medicine and Surgery, University of Malta Medical School, Malta; ⁵Department of Surgery, Division of Interventional Sciences, University College London, London, United Kingdom; ⁶Rookwood Rehabilitation Hospital Cardiff, Wales, United Kingdom; ⁷Welsh Centre for Plastic Surgery, Morriston Hospital, Abertawe, Wales, United Kingdom; ⁸Department of Surgery, Imperial College, London, United Kingdom; ⁹Laserplast Srl Stp, Milan, Italy

ABSTRACT

Amputation is a common military and civilian surgery with high morbidity. Patients without prostheses due to neuroma pain lose productivity and lifelong contributions, which is often underestimated. The surgical and non-surgical treatment of painful stump neuromas is controversial. An evidence-based assessment and cost-benefit analysis of painful stump neuroma management modalities emphasizes institutional awareness and disruptive technologies. An Oxford Centre for Evidence Based Methodology critical appraisal and structured literature review were used in the research. We found 154 records using a reproducible literature search strategy that included electronic databases and references. A full review of 27 manuscripts after exclusion criteria yielded data for analysis. Surgical, injectable, and electromagnetic spectrum methods were used. Surgical interventions had longer follow-up times than injection and radiofrequency treatments, which affected outcomes. CEBM level 4 evidence dominated primary literature, indicating low quality. No therapy was superior, but the risks varied. Injection therapies like sclerosing alcohol had limited success and side effects. Despite limited evidence, electromagnetic spectrum modalities showed potential. Including direct and indirect costs, amputation stump refitting costs millions annually. Compared to outpatient non-surgical interventions, laser therapy could save a lot of money. According to the study, surgical interventions are common but expensive and have limited functional success. Low-risk non-surgical methods like co-ablation, pulsed radiofrequency, and transcutaneous laser therapy have mixed results. The short follow-up of all non-surgical studies seems to limit them. Follow-up duration is crucial to outcome assessment. Long-term, low-risk laser-induced thermotherapy is promising for future research. This study emphasizes the need for more research and the economic benefits of disruptive technologies in treating painful stump neuromas.

Key words: amputation; neuroma; cost-benefit; laser.

Corresponding author:

Ernest Azzopardi, Department of Anatomy, Faculty of Medicine and Surgery,
University of Malta Medical School, Malta.
E-mail: info@skinsurgeon.eu

Received: 30 May 2023.
Accepted: 23 August 2023.

Introduction

Amputations is a common surgical procedure, within both military and civilian life.^{1,2} Amputation carries a high morbidity.³ In the USA, 134,000 amputations are performed annually,⁴ A patient who, for any reason, cannot wear their prosthesis, suffers significant and often understated economic cost, with a domino effect on lifetime economic productivity and contribution. Neuroma pain is a major cause of morbidity and prosthesis re-fashioning. Literature reports multiple modalities of treatment – both surgical and non-surgical, in current use, to address painful stump neuromas.

Management of painful stump neuromas does not currently benefit from consensus. Within the UK, the American Pain Society only provides guidelines for opioid treatment in non-cancer pain and interventional management for back pain, and no European guidelines were identified.⁵ More recent literature reports a change in approach to the identification and multi-modality management of the underlying mechanisms, such as supraspinal, spinal, and peripheral.⁶ This manuscript undertakes an appraisal and cost-benefit analysis for the major modalities of management, and institutional awareness and explores novel, disruptive technology.

Materials and Methods

This study applied an evidence-based critical appraisal of the literature methodology in order arrive to at its recommendations.⁷ This methodology is based on a reproducible search of the literature, followed by a comparative analysis of the literature, and is suitable for analysis of a heterogenous coterie of studies such as the one in this study. This method is well-established in the literature.⁸⁻¹⁰

Search strategy

An electronic search for primary literature was performed on the following search engines: MEDLINE, PubMed, Embase, Cochrane Library, Ovid Sp. (January 1990 onward). A broad Boolean search string was performed using the search string with truncated headings as follows: “neuroma*” AND “pain*” AND amputation AND (treatment OR cost OR cost-benefit). Mesh head-

ings were also examined for other relevant terms relating to the various techniques used in painful neuroma management. Web Knowledge™ was used to forward- and back-reference the primary literature. Following the screening of titles and abstracts, experimental studies, studies investigating mixed mechanism injury, and those not exclusively involving amputation data were excluded from further analysis. Studies investigating phantom pain, pharmacotherapy, complementary therapy, central nervous system, non-limb injury, and non-human studies were excluded. Due to the scarcity of high-quality data supporting the interventions, a literature synthesis rather than systematic review and metaanalysis was performed.^{11,12}

The search returned 154 records. The Cochrane Library returned no result. Following the application of exclusion criteria and removal of duplicated material, through a Boolean search using the NOT prefix, 132 manuscripts were excluded. Web of Knowledge referencing included a further 7 manuscripts. These 27 manuscripts were read in full and a further 13 studies were excluded (Figure 1).

Results

Quality of the evidence

The majority of primary literature identified in this study reports on various surgical techniques. These include traction neurectomy, vein implantation, burial technique, perineural adhesion, and nerve-to-nerve adhesion. Sehirlioglu *et al.*¹⁴ demonstrated that the formation of neuromas takes approximately 12 months to form, yet 9 of 14 studies had shorter follow-up periods which suggests an overestimation of the true, long-term potential of some interventions. Primary literature reporting on surgical interventions reports an average follow-up time of 31±7 months (mean ±SD) (Table 1). Injectable/cryoablation methods on the other hand had a substantially shorter followup time of 7±4.5 months (mean±SD). Non-surgical interventions, on the other hand, had an average follow-up time of 4.7±1.9 months (mean±SD), with one exception, where three neuromas treated with laser were followed up for 8 years. It is therefore clear that in the present literature, follow-up time is a major source of bias when compar-

ing surgical to injection and radiofrequency treatment. A single and notable exception is Algermissen *et al.*, who used laser-induced thermotherapy, and followed up patients for 8 years. Unfortunately, only three patients were included in this case series. A methodological appraisal of the manuscript against the Oxford

Centre for Evidence Based Medicine’s hierarchy of evidence²⁷ suggests that current literature is based on evidence of limited quality, and mostly based on level 4 evidence (Table 1, 2 and 3).

A recent, well-conducted systematic review reports that no single therapeutic modality showed superiority.³

Table 1. Currently used modalities in the literature – surgical.

Technique	Study (<i>et al.</i>)	Study size/type/ evidence level	Outcome	Mean follow-up (months)	Comments
Neurectomy muscle-reimplant	Ducic ¹³	21 Retrospective cohort Level 4	Mean VAS reduction from 8.04 to 1.07	22.8	15 AKA/BKA; 6 UL
Traction Neurectomy	Sehirlioglu ¹⁴	75 Retrospective case series Level 4	All pain-free at follow up	33.6	No mention of pain measurement tools No detail of surgical methodology
Traction neurectomy	Pet ¹⁵	38 Retrospective case series Level 4	58% pain free	37	24% Lost to follow up No radiology to document diagnosis or follow-up

AKA, above knee amputation; BKA, below knee amputation; UL, upper limb; VAS, visual analog scale.

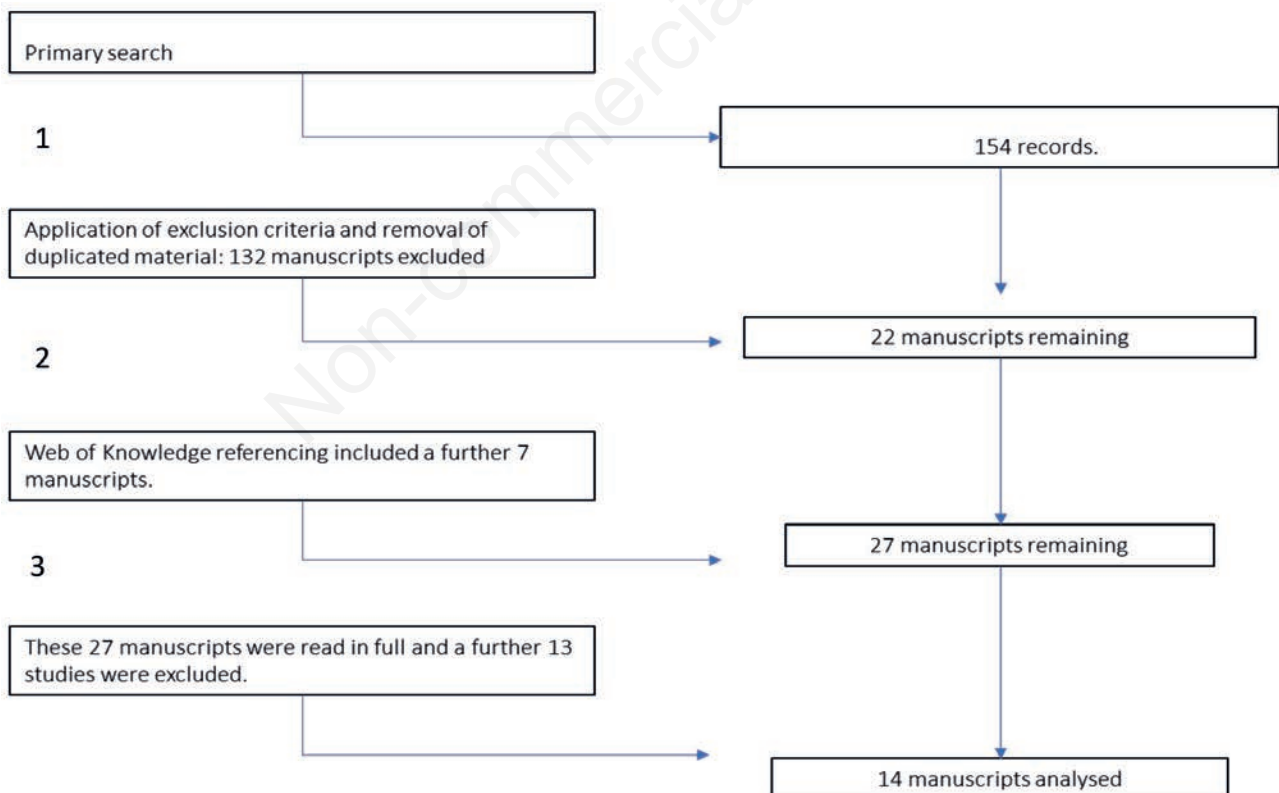


Figure 1. Literature search strategy.

Table 3. Currently used modalities of management: electromagnetic spectrum.

Technique	Study (<i>et al.</i>)	Study size/type/ evidence level	Outcome	Mean follow-up (months)	Comments
Coblation	Zhang ¹⁷	1 AKA Case report Level 5	VAS score: Pain reduced from 8-2/10	6	Used US imaging fordiagnosis and as therapy aid
Pulsed RF	Kim ²¹	1 AKA Case report Level 5	Decreased VAS score 8.5-4.5 on wearing prosthesis	6	Short follow-up Used steroid injection in addition to PRFUS used for diagnosisbut not follow-up
US guided Pulsed RF	Restreop-Garces ²²	1 BKA Case report Level 5	VAS score reduced from10 to 3	6	US not used for follow up
US guided Pulsed RF	West ²³	4 BKA case series	VAS scores at 6 months 5-8 point reduction	6	Short follow-up time Small sample VAS not mentioned for one case No complications were reported
Pulsed RF	Wilkes ²⁴	1 BKA Case report Level 5	VAS score	4	Low-quality evidence
Transcutaneous laser	Gimber ²⁵	31 Morton's neuromas Retrospective review Level 4	In 93% of neuromas, pain was reduced or absent	1.7	Short follow-up time
Laser-induced thermotherapy (single fiber)	Algermissen ²⁶	3 Case series Level 4	100% reduction in pain	48-56	Small sample but substantial follow-up

RF, radiofrequency; US, ultrasound; BKA, below knee amputation AKA, above knee amputation; VAS, visual analog scale; US, ultrasound.

Table 2. Currently used modalities in the literature – injectable.

Technique	Study (<i>et al.</i>)	Study size/type/ evidence level	Outcome	Mean follow-up (months)	Comments
Alcohol injection	Lim ¹⁶	2 (Case reports) Level 5	Mean VAS reduction in pain: case one (1:10 to 3; case two 8.5 to 4)	3	Short follow-up, small sample, US used to visualize neuroma but not used in followup
Alcohol injection + RF (US guided)	Zhang ¹⁷	13 Prospective unmatched cohort	54% achieved pain relief after 3 alcohol injections	6	Scores for different types of pain given, difficult to assess overall result
Phenol injection	Gruber ¹⁸	82 Prospective cohort Level 4	VAS score: 13% pain-free at 6m; 25% nearly pain-free; 10% minor complication rate	6	Small size; poor patient compliance; 5.8% minor complication rate; 1.3% major complication
Cryoablation	Neumann ¹⁹	10 Case series Level 4	Three-step pain scale At 12 months, 3 patients had pain better to before treatment, but 7 patients had recurring pain	12	Anecdotal evidence No other outcomes mentioned One patient reported pain being worseafter treatment
Steroid injection	Kesikburun ²⁰	14 Cohort no control Level 4	Mean VAS score 7.6 to 3.5 on prosthesis 21% of patients failed management	6	Limited study duration, no controls

VAS, visual analog scale; US, ultrasound.; RF, radiofrequency; US, ultrasound.

Even within this review, the 4 treatment modalities reporting the highest promise (targeted nerve implantation, traction neurectomy, nerve-to-nerve anastomosis, and perineurial gluing) were based on studies limited by short follow-up times. Interventions do, however, vary by the risk of harm, therefore there is a secondary morbidity associated with the intervention itself.

Critical appraisal of management methods

Post-amputation neuroma pain is cited as one of the 5 main reasons for surgical revision. While the complication rates of revision amputation are extensively discussed elsewhere, outcomes regarding the primary therapeutic (as opposed to surgical) outcomes are infrequently reported. A recent study by Bourke *et al.* illustrates this difference, whilst surgical success was reported to be around 50%. only 12.5% reported an improvement in SIGAM (Special Interest Group in Amputee Medicine) scores.²⁸

Moreover, none of these studies mention the method by which the nerves are transected. Nor do they specify the loss to follow-up, the specificity of the symptom studied to neuroma recurrence.

Injection therapies (alcohol, phenol, steroids, and cryoablation)

Follow-up data for patients undergoing phenol injection is particularly scarce and limited to six months. The included study reports a high dropout rate for the total course of three phenol injections per neuroma. Phenol injections reported a high incidence of side effects including a 10% minor complication rate and a 3.8% rate of soft tissue necrosis. In the same study, no patient was free at 6 months (the follow-up reported) despite it being well-known that neuroma reformation occurs around the 12-month benchmark. Injection of sclerosing alcohol is currently supported as an effective method by the limited level 5 evidence (Table 2).

Although there is some experimental evidence to suggest that post cryoablation, neuronal re-growth is more organized, this is not yet borne out by the available evidence, where 70% of patients had recurring pain (or in one patient, worse pain) at the 12-month benchmark (Table 2).³ Steroid injection is supported by one study of a small sample size, with no comparator group, with

a short follow-up (Table 2). Moreover, the study does not mention there are any complications, and for this reason, it is difficult to debate the risk-benefit of steroid injections.

Management using electromagnetic spectrum modalities

Studies regarding coblation, pulsed radiofrequency, and ultrasound-guided pulsed radiofrequency are currently limited to level 4 and level 5 evidence, with case numbers not exceeding 4 patients per study, and with no longer than 6 months' duration. Despite these limitations, no side effects were reported. Therefore low quality evidence supports its use as a low-risk, modest success modality.

Cost-benefit analysis

Recent data show that a total of £2,070,073 non-pay costs are associated with amputation stump refitting per year in Scotland (Table 4).

Assuming a direct correlation between Scotland and the rest of the UK (64 million), this is extrapolated into a cost of £26,491,693.4. This notional value excludes salary costs of rehabilitation and inpatient costs. It also excludes the full economic cost of the labor market. A conservative estimate for 173 operations at £1000 per hour and 2 h operating turnaround time is £1,730,000. This translates into a conservative estimate of £28,221,196.4. Revisions for neuromas account for approximately 15-30% of the total throughput. A civilian conservative estimate of the direct costs associated with the problem in the UK is £4.3 to 8.6 million per year. Considering the multiplier effect on a 40-year-old amputee with 25 years of working life affected at 50% of minimum salary cost, a conservative estimate of the lifetime cost to the economy is £432,000,000.

Table 4. Yearly non-pay cost of amputation stump re-fits in Scotland UK per item, excluding rehabilitation (population 5.3 million).

Item	Multiples	Cost
Microprocessor knees	33	1,300,191.33
Hydraulic and smart ankles	116	410,116
Multiarticulating hands	8	214483
Sporting devices	16	97,381

Cost analysis

Operating suites represent some of the costliest areas of hospitals in the UK with an average cost of £1200 per hour.²⁹ Added to this are the costs associated with variable recovery times, requirement for higher dependency areas, hospital bed-stays, and follow-up management. Additionally, the operating suite represents a mix of both fixed and variable costs.

In contrast, non-surgical procedures that can be performed on an outpatient basis are estimated to cost the UK NHS between £95 -500 per new patient appointment, or approximately US\$ 35.5 per minute of operating time in the USA.^{30,31} In addition, fixed capital expenditure (CAPEX) costs may also need to be factored into this equation. This variable may be more important when considering novel therapeutic modalities.

The cost-effectiveness of laser therapy compared to surgical interventions has been extensively studied and investigated in various contexts. Two prominent studies concur on the potential benefits, which encompass not only direct and indirect advantages to healthcare institutions but also broader ripple effects on the overall economy. Hulltmann *et al.*, in a comprehensive study involving 800 patients, suggest that the application of laser therapy for hypertrophic burn scars substantially reduces expenditures for healthcare providers, insurers, and patients alike.³² Miletta *et al.* corroborates these same findings across an expansive spectrum of military procedures, affirming that the implementation of laser services leads to efficacious and economically sound management with decreased complications.³³

Our independent study, which analyzes the patterns in resource utilization for secondary burn reconstruction across more than 22 years at a prominent tertiary hospital in the United Kingdom, goes beyond simply establishing an inverse relationship between increased laser therapy usage and burn surgery procedures. We identify a consistent trend: minor increments in laser therapy yield substantial reductions in secondary burn surgeries performed at the same institution, amounting to a notable 47.3% decrease in such surgeries. Additionally, rates of complications following laser surgery are less frequent and less severe compared to traditional surgery, resulting in an accumulative decrease in the overall service costs, as well as associated support services like infection control and intensive care.³⁴ Similarly, in our recent paper discussing a 5-year follow-up of patients with cut-

aneous basal cell carcinoma treated with carbon dioxide-assisted Photodynamic therapy, we reported a saving of £235 per basal cell carcinoma. At NHS at 2015 prices, that equated with a 43% saving, or a national annualised saving of £70 million by 2025 for the NHS.³⁵ Although the evidence for the laser is at this stage only reliant on case series, it is worth mentioning that these case series have a much longer follow-up than the plethora of other studies in the tables above. The potential for significant cost savings if this therapy were to be developed further, is therefore worth exploring.

Novel therapeutic modalities and direction of future research

Single-fiber Laser-induced thermotherapy (LITT) has been reported in a single study that uses solid-state lasers, and single fiberoptics to precisely deliver energy to target nerves. Evidence is currently limited to a Level 4 study in humans. However, this case series benefitted from a remarkable follow-up time of up to 8 years (Table 3). LITT is well-established in neurosurgery for the selective ablation of brain tumors, first introduced by Brown in 1983, and has since been revisited and refined in light of new technical advancements in the field.³⁶ Recent technical advancement allows super-selective ablation of brain tissue under MRI control, achieving selective thermal injury of pathological tissue while maintaining a sharp thermal border between the tumor and normal brain tissues.³⁷ Future studies in this direction would represent a worthwhile direction of travel considering that solid-state, single fiber optic systems are generally less expensive to maintain, are more robust and the procedures may be performed in an outpatient setting.

Recommendations

Considering the current best evidence available, surgery continues to be the therapeutic modality underscored by level 4 evidence with adequate follow-up times. However functional (as opposed to surgical) success rates are limited for what is one of the more expensive procedures analyzed in this study (Grade of recommendation: C). Limited level 5 evidence supports the use of Coblation; Pulsed radiofrequency, ultrasound-guided pulsed radiofrequency, as a low-risk intervention of modest medium-term success. All studies lack adequate follow-up time.

(Grade of recommendation: D). Level 5 evidence reports that phenol injection does not have any particular advantage over other non-surgical modalities but is linked to a higher incidence of minor and major side effects, for this reason, it should not be recommended for non-experts (Grade of recommendation: D). Transcutaneous laser applications show promise as a long-term, low-risk, and cost-effective solution which merits further investigation.

Conflict of interest: the authors declare no potential conflict of interest, and all authors confirm accuracy.

Ethics approval: not applicable.

Informed consent: not applicable.

Patient consent for publication: not applicable.

Availability of data and materials: all data generated or analyzed during this study are included in this published article.

References

- 1 Beekley AC, Sebesta JA, Blackbourne LH, et al. Prehospital tourniquet use in Operation Iraqi Freedom: effect on hemorrhage control and outcomes. *J Trauma* 2008;64:S28-37; discussion S37.
- 2 Ploeg AJ, Lardenoye JW, Vrancken Peeters MP, Breslau PJ. Contemporary series of morbidity and mortality after lower limb amputation. *Eur J Vasc Endovasc Surg* 2005;29:633-7.
- 3 Poyntz SA, Hacking NM, Dalal M, Fowler S. Peripheral Interventions for Painful Stump Neuromas of the Lower Limb: A Systematic Review. *Clin J Pain* 2018;34:285-295.
- 4 Kay, M. & Marshall, C. Indications and Management of Lower Limb Amputation. *Postgraduate Vascular Surgery: A Candidate's Guide to the FRCS and Board Exams*. 2018.
- 5 Chou R, Fanciullo GJ, Fine PG, et al. Clinical guidelines for the use of chronic opioid therapy in chronic noncancer pain. *J Pain* 2009;10:113-30.
- 6 Hsu E, Cohen SP. Postamputation pain: epidemiology, mechanisms, and treatment. *J Pain Res* 2013;6:121-36.
- 7 Sackett DL, Rosenberg WM. The need for evidence-based medicine. *J R Soc Med* 1995;88:620-4.
- 8 Umesh G, Karippacheril JG, Magazine R. Critical appraisal of published literature. *Indian J Anaesth* 2016;60:670-673.
- 9 Azzopardi EA, Boyce DE, Dickson WA, et al. Application of topical negative pressure (vacuum-assisted closure) to split-thickness skin grafts: a structured evidence-based review. *Ann Plast Surg* 2013;70:23-9.
- 10 Azzopardi EA, Whitaker IS. Acute pain management during facial injection of botulinum toxin: an evidence-based systematic review. *Plast Reconstr Surg* 2010;125:162e-164e.
- 11 Harsh S, Clarke D. Advancements in Research Synthesis Methods: From a Methodologically Inclusive Perspective. *Rev Educ Res* 2009;79:395-430.
- 12 Whittemore R, Chao A, Jang M, et al. Methods for knowledge synthesis: an overview. *Heart Lung* 2014;43:453-61.
- 13 Ducic I, Mesbahi AN, Attinger CE, Graw K. The role of peripheral nerve surgery in the treatment of chronic pain associated with amputation stumps. *Plast Reconstr Surg* 2008;121:908-914.
- 14 Schirlioglu A, Ozturk C, Yazicioglu K, et al. Painful neuroma requiring surgical excision after lower limb amputation caused by landmine explosions. *Int Orthop* 2009;33:533-6.
- 15 Pet MA, Ko JH, Friedly JL, Smith DG. Traction Neurectomy for Treatment of Painful Residual Limb Neuroma in Lower Extremity Amputees. *J Orthop Trauma* 2015;29:e321-5.
- 16 Lim KB, Kim YS, Kim JA. Sonographically guided alcohol injection in painful stump neuroma. *Ann Rehabil Med* 2012;36:404-8.
- 17 Zhang X, Xu Y, Zhou J, et al. Ultrasound-guided alcohol neurolysis and radiofrequency ablation of painful stump neuroma: effective treatments for post-amputation pain. *J Pain Res* 2017;10:295-302.
- 18 Galiano K, Strasak A, Peer S. Practical experience with sonographically guided phenol instillation of stump neuroma: predictors of effects, success, and outcome. *AJR Am J Roentgenol* 2008;190:1263-9.
- 19 Neumann V, O'Connor RJ, Bush D. Cryoprobe treatment: an alternative to phenol injections for painful neuromas after amputation. *AJR Am J Roentgenol* 2008;191:W313; author reply W314.
- 20 Kesikburun S, Yaşar E, Dede I, Göktepe S, Tan AK. Ultrasound-guided steroid injection in the treatment of stump neuroma: pilot study. *J Back Musculoskelet Rehabil* 2014;27:275-9.
- 21 Kim YK, Jung I, Lee CH, et al. Pulsed radiofrequency ablation under ultrasound guidance for huge neuroma. *Korean J Pain* 2014;27:290-3.
- 22 Restrepo-Garces CE, Marinov A, McHardy P, et al. Pulsed radiofrequency under ultrasound guidance for persistent stump-neuroma pain. *Pain Pract* 2011;11:98-102.
- 23 West M, Wu H. Pulsed radiofrequency ablation for residual and phantom limb pain: a case series. *Pain Pract* 2010;10:485-91.
- 24 Wilkes D, Ganceres N, Solanki D, Hayes M. Pulsed radiofrequency treatment of lower extremity phantom limb pain. *Clin J Pain* 2008;24:736-9.
- 25 Gimber LH, Melville DM, Bocian DA, et al. Ultrasound Evaluation of Morton Neuroma Before and After Laser Therapy. *AJR Am J Roentgenol* 2017;208:380-385.
- 26 Algermissen B, Philipp CM, Müller U, Urban P, Berlien H-P. Interstitial Thermoablation (ITT) using Nd: YAG Laser as a new option for the treatment of Neuroma. *Medical Laser Application* 2001;16:129-134.

- 27 Phillips, B. et al. Oxford centre for evidence-based medicine levels of evidence (May 2001). *BJU international* 2011;107:870.
- 28 Bourke HE, Yelden KC, Robinson KP, Sooriakumaran S, Ward DA. Is revision surgery following lower-limb amputation a worthwhile procedure? A retrospective review of 71 cases. *Injury* 2011;42:660-6.
- 29 Fletcher D, Edwards D, Tolchard S, Baker R, Berstock J. Improving theatre turnaround time. *BMJ Qual Improv Rep* 2017;6:u219831.w8131.
- 30 Edwards, N. Reducing outpatient activity does not cut costs. *BMJ* 2018;361:k1826.
- 31 Childers CP, Maggard-Gibbons M. Understanding Costs of Care in the Operating Room. *JAMA Surg* 2018;153:e176233.
- 32 Hultman CS, Edkins RE, Lee CN, Calvert CT, Cairns BA. Shine on: Review of Laser- and Light-Based Therapies for the Treatment of Burn Scars. *Dermatol Res Pract* 2012;2012:243651.
- 33 Miletta NR, Donelan MB, Hivnor CM. Management of trauma and burn scars: the dermatologist's role in expanding patient access to care. *Cutis* 2017;100:18-20.
- 34 Azzopardi EA, Duncan RT, Kearns M, et al. Cutaneous laser surgery for secondary burn reconstruction: Cost benefit analysis. *Burns* 2020;46:561-566.
- 35 Azzopardi EA, Abdelrahman W, Azzopardi E, et al. Treatment of cutaneous basal cell carcinoma with combined laser extirpation and methyl aminolevulinic acid: five-year success rates. *Ann R Coll Surg Engl* 2021;103:263-271.
- 36 Silva D, Sharma M, Barnett GH. Laser Ablation vs Open Resection for Deep-Seated Tumors: Evidence for Laser Ablation. *Neurosurgery* 2016;63:15-26.
- 37 Belykh E, Yagmurulu K, Martirosyan NL, et al. Laser application in neurosurgery. *Surg Neurol Int* 2017;8:274.

Non-commercial use only