
Endolift® the “lunch-time” laser lifting for the lower eyelids: Case report

Roberto Dell’Avanzato

Medical Aesthetic Department, Espace Chenot Health Wellness SPA at L’Albereta Relais & Chateaux, Erbusco (BS), Italy

ABSTRACT

Lasers and others energy-based devices have reached very high levels of results. Although the area of the lower eyelids is one of the most difficult to treat without surgery, Endolift® represents one of the safest and effective techniques that we can offer. Endolift® procedure was performed with a 200 microns second-generation bare fiber connected to an Italian 1470nm semiconductor laser to treat the lower eyelids of a 43-year-old patient with wrinkles and skin laxity. No anesthesia was required. The fiber was easily inserted through the skin, without any incisions, directly between the orbicularis oculi muscle and the septum. The total laser energy delivered was 80 J for each side. Post-procedure the patient immediately resumed her daily activities. Snap Back test was performed before (T0) and 6 months (T1) after the procedure; Fitzpatrick “wrinkle score” and “degree of elastosis” were assessed at T0 and T1; investigator Global Aesthetic Improvement scale (iGAIS), external investigator Global Aesthetic Improvement scale (eiGAIS) and participant Global Aesthetic Improvement scale (pGAIS) were also recorded at T1. The treatment has been completed with a session of a vascular 532nm diode laser for treating the fine telangiectasias, immediately before the Endolift® procedure. The lower eyelids have benefited from the possibility that the Endolift® has to remodel and retract the tissues, activate the collagen production, and stimulate the neo-angiogenesis. Results are evaluated at T1, when the skin laxity is reduced and superficial wrinkles are smoothed, resulting in an overall compacting of the skin which is visible and continues to progress over the following months. The only adverse events recorded were redness for 3 hours and a light swelling for 2 days. Snap Back test at T0 was severe and negative at T1; at T0 wrinkle score” was II and Fitzpatrick “degree of elastosis” was 7-9 but at T1 Fitzpatrick “wrinkle score” was I and Fitzpatrick “degree of elastosis” was 1-3; iGAIS, eiGAIS and pGAIS at T1 were all +3. Endolift® can currently be considered one of the leading non-surgical treatments for the laxity of lower eyelids.

Key words: Endolift®; laser, skin laxity; lower eyelids; optical fibre.

***Running Head:**

Endolift for lower eyelids

Corresponding author:

Roberto Dell’Avanzato

Telephone: +39.3316582739

Email: dellavanzato@hotmail.it

Introduction

In the past few years, laser and others energy-based devices has gained increasingly high popularity in aesthetic medicine. Particularly, lasers have reached very high levels of results. Endolift® represent a minimally invasive outpatient laser procedure used in endo-tissutal (interstitial) aesthetic medicine, of which Dr. Roberto Dell'Avanzato is considered the former inventor and the developer.¹⁻⁴ The treatment was performed with a 1470nm solid state semiconductor laser, using a disposable micro-optical fiber, able to rejuvenate the skin and remodel the connective tissue, stimulate the new collagen production and promoting skin tightening.⁵ Although the area of the lower eyelids is one of the most difficult to be treated without surgery, Endolift® represents one of the safest and effective techniques that we can offer patients.

Case Report

Is here reported the result of a 43 years-old patient (Figure 1) with wrinkles and skin laxity in the lower eyelids, treated with a single session of Endolift®. Before starting the session, the area was carefully evaluated and the patient was informed, through an informed consent form, about the contraindications, warnings and possible complications arising from the treatment. The form was returned signed. In addition, the patient signed a consent form, to authorize the publication of her data (e.g. clinical information, photographic material). The area was cleaned using a make-up remover solution, photographed, and delimited with the dermographic

pen, keeping the patient upright. Then, the patient was positioned on a flatbed and equipped with ocular shields and the area was disinfected with non-alcoholic solution. The laser settings were: emission mode Pulsed, Power 2 Watts, Ton 25msec, Toff 75 msec. No kind of anesthesia was required. A 200 micron of a second generation FTF (Fiber to Fiber) bare fibre connected to an Italian 1470nm semiconductor laser (Eufoton® – Italy) was used to treat the lower eyelids of the patient. The bare fiber was easily inserted through the skin, without any incisions, directly between the orbicularis oculi muscle and the septum. The entrance point was localized 1cm inferiorly to the lateral cantum. The total laser energy delivered was 80 J for each side. The session has been completed with the treatment of fine telangiectasias with a 532nm diode laser, immediately before the Endolift® procedure. Post-procedure the patient can immediately resume her activities of daily life. Adverse events were also recoded: erythema, edema, hematoma, skin burning, hitching, pain. Results are evaluated after 6 months (T1) (Figure 2). Snap Back test was performed before (T0) and at T1; Fitzpatrick “wrinkle score” and “degree of elastosis” were assessed at T0 and T1; investigator Global Aesthetic Improvement scale (iGAIS), external investigator Global Aesthetic Improvement scale (eiGAIS) and participant Global Aesthetic Improvement scale (pGAIS) were also recorded at T1.

Discussion

After 17 years of personal experience on Endolift® technique, it is possible to affirm that slight and moderate

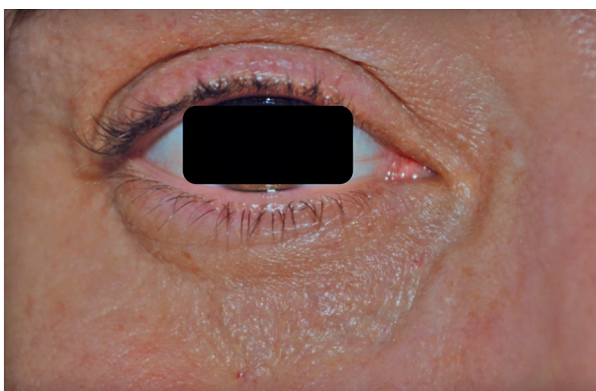


Figure 1. Pre-treatment appearance of the lower eyelid. The wrinkles and skin laxity of the lower eyelid are evident. 108x71 mm (300x300 DPI).

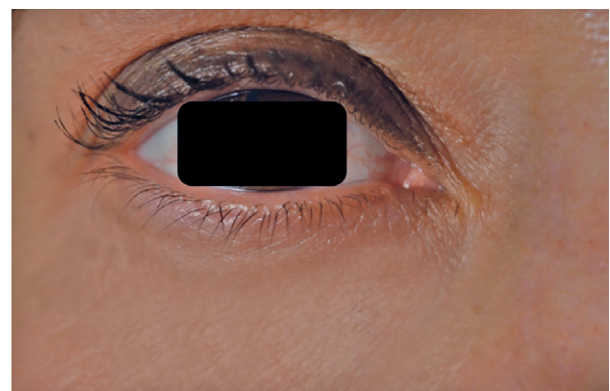


Figure 2. Post-treatment appearance of the lower eyelid after 6 months (T1). The skin laxity is reduced, and superficial wrinkles are smoothed. 102x81 mm (300x300 DPI).

flabbiness in face, neck and body areas can fully benefit from the intratissutal laser to remodel skin, stimulate neocollagenesis and, due to the wavelength of 1470nm, selectively interact with water in the skin, resulting in a visible and long-lasting “lifting effect”.

Disposable micro-optical fibers exist in bare version (flat/linear) or ring version (annular/radial). Here we used a 200 microns bare fiber that permit the emission of the laser energy frontally with an angle of 37°; instead, radial fibre in this area could be risky due to the lateral emission of the energy that can affect an area of 4.5-5mm; lastly, fibers bigger than 200 microns can also be used but results in a more painful treatment in this delicate area (300 or 400 microns). Total energy delivered for each side was 80 J and its calculated considering two main criteria: the first is the theoretical tissue's volume and energy ratio where for each cm² the average amount is 10 J therefore for an area like the lower eyelids (4x2 cm) 80 J is considered the correct quantity; the second criteria is the clinical experience over thousands of treatments performed worldwide by hundreds doctors, whose data are sent to the Eufoton® company through the opinion leader or the distributors, and 60-120 J is the range of energy more used to treat this area.⁶⁻¹⁰

The session has been completed with the treatment of fine telangiectasias with a 532nm diode laser, immediately before the Endolift® procedure.

The Snap Back test at T0 was severe and negative at T1; Fitzpatrick “wrinkle score” was II (moderate-depth wrinkles, numerous lines with redundant skin folds) at T0 and Fitzpatrick “degree of elastosis” was 7-9 (severe elastosis) at T0 but at T1 Fitzpatrick “wrinkle score” was I (fine wrinkles) and Fitzpatrick “degree of elastosis” was 1-3 (mild elastosis); iGAIS, eiGAIS and pGAIS at T1 were all +3 (very much improved). The only adverse events recorded were redness for 3 hours and a light swelling for 2 days.

Conclusions

The lower eyelids, as well as different areas of the face, neck and body, have benefited from the possibility that Endolift® has to retract and remodel the tissues, activate the collagen production and stimulate the neo-angiogenesis, resulting in an overall compacting of the skin which continues to progress over the following months after treatment.

Endolift® can currently be considered one of the leading non-surgical treatments for the wrinkles and the laxity of lower eyelids, safe, effective, repeatable, reproducible and replicable.

Acknowledgements: The author have provided a significant contribution in the study by observing and having a correct follow up of the patient, and in the manuscript preparation.

Conflict of interest: The author has stated explicitly that there are no conflicts of interest in connection with this article.

Availability of data and materials: All data underlying the findings are fully available.

Ethics approval and consent to participate: Not applicable.

Consent for publication: Not applicable.

References

1. Dell'Avanzato R. Endolift and soft laser resurfacing. In: XV Jornadas Mediterraneas de confrontaciones terapeuticas en medicina y cirurgia cosmetica. May 4-6, 2007; Sitges, Spain.
2. Dell'Avanzato R. Endolift®: the instantaneous laser lift with no downtime. *Aesthetic Medicine* (Chapter 15-1). Minerva Medica Editore.
3. Dell'Avanzato R, Bovani B. Endolift: laser a fibra ottica sottocutanea per il trattamento delle lassità cutanee. *Body contouring* (p. 73-82). OEO Editore.
4. Antiaging Lifting-Laser Tightening Skin. Facial rejuvenation with Laser. Available from: <https://youtu.be/DeLYM6k1uSA?list=PL804AD848350D5C35>
5. Endolift® Clinical reference manual. Made in collaboration with Eufoton medical board. 2015.
6. Nilforoushzadeh MA, Fakhim T, Heidari-Kharaji M, et al. Efficacy evaluation of Endolift-based Subcision on acne scar treatment. *J Cosmet Dermatol* 2021;20: 2579-82.
7. Nilforoushzadeh MA, Heidari-Kharaji M, Fakhim T, et al. Endolift laser an effective method for the lower eye bag treatment: a case series study. *Lasers Med Sci* 2022;37:3123-8.
8. Nilforoushzadeh MA, Fakhim T, Heidari-Kharaji M, et al. Endolift laser an effective treatment modality for forehead wrinkles and frown line. *J Cosmet Dermatol* 2022;21:2463-68.
9. Nilforoushzadeh MA, Heidari-Kharaji M, Fakhim T, et al. Endolift laser for jowl fat reduction: clinical evaluation and biometric measurement. *Lasers Med Sci* 2022;37:2397-2401.
10. Nilforoushzadeh MA, Heidari-Kharaji M, Behrangi E, et al. Effect of Endolift laser on upper eyelid and eyebrow ptosis treatment. *J Cosmet Dermatol* 2022;21:3380-5.