

Use of laser in oral frenectomies: a case report series

Jean-Paul Rocca¹, Nathalie Brulat-Bouchard², Christine Voha³, Hèlène Raybaud³, Caroline Bertrand⁴, Carlo Fornaini^{1,5*}

¹University Côte d'Azur, Micoralis Research Laboratory UPR7354, Nice, France

²Department of Restorative Dentistry and Endodontics, Faculty of Dentistry, University of Cote d'Azur, Nice, France

³Pôle Odontologie, CHU Nice Saint Roch, Nice, France

⁴Université de Bordeaux, UFR d'Odontologie, Bordeaux, France

⁵University of Parma, Department of Engineering and Architecture, Parma, Italy

ABSTRACT

The aim of these case report series concerns the use of laser technology in oral frenectomies, by discussing different methods as well as comparing different laser wavelengths and underlining the role of photobiomodulation in the healing process.

Key words: Laser, Oral Surgery, Frenectomy, Orthodontics, Periodontics

Introduction

In a not so far time, rotative devices for conservative treatments and bone surgery and cold blades for soft tissues surgery were the only instruments used even if several critical points have been described by many authors [1, 2].

Recently, the use of new technologies, such laser, piezo-surgery and quantic molecular resonance has significantly increased and laser technology, thanks to its possibility to reduce or eliminate the use of anesthetic injection, to avoid use of sutures and to make a better and faster healing process, seems to be able to play an important role for discomfort reduction and, consequently, patient compliance increase [3].

Frenectomy is a minor oral surgical procedure that may concern different locations and situations: lingual, upper vestibular and lower vestibular.

Lingual frenectomy is suggested in presence of an abnormal short lingual frenulum, also called "ankyloglossia" or "tongue-tie": this is a condition in which the tip of the tongue cannot protrude over the incisors and it is often associated to several orthodontic diseases such as total open bite and class third malocclusion [4].

This anomaly may be classified in function of the distance measure between frenulum insertion and tongue tip while patient is touching the palate with mouth opened, allowing to distinguish four different classes of severity [5]. Anchyloglossia has a great importance in the deglutition and phonation functional re-education: speech therapists suggest

*Running title:

Laser in oral frenectomies

Corresponding Author:

Fornaini Carlo, Micoralis Research Laboratory UPR7354, Université Nice Côte d'Azur
Faculté de Chirurgie dentaire, Site St Jean d'Angély Bat. SJ2, 5, rue du 22ème BCA 06300 Nice
Tel. +39 332014393
Email: carlo@fornainident.it

surgical frenectomy when patients cannot do the exercises due to the tongue movement limitation [6]. Upper vestibular frenectomy is indicated, when related to inter-incisive diastema, if frenum is attached to the papillary gingiva (positive traction test) or if the distance between central incisors is larger than 6-8 mm. The intervention, beyond the elimination of frenulum insertion, must also cut the inter-incisive fibers until to reach the periosteum, in order to allow the space closure [7, 8].

In some cases, when the intervention is done choosing a correct timing during denture development, it may be sufficient to reach a good result without a classical orthodontic treatment and without appliance wearing [9].

Lower vestibular frenum abnormal insertion is often related to periodontal problems. In fact, In the mandibular anterior area, gingival recession can be associated with a minimal amount or lack of attached gingiva, a shallow vestibule, and high frenum insertion and these anatomical features may preclude the use of traditional root coverage procedures [10].

When the laser energy is emitted on the target tissue it may be reflected, transmitted, diffuse or absorbed and this last interaction, absorption, is necessary to obtain the surgical effect of tissue ablation. This is possible because biological soft tissues contain water, proteins and some coloured pigments such haemoglobin and melanin, each of them able to absorb a specific range of laser wavelengths. Even if most of lasers used in dentistry emit in infrared portion of the spectrum, in the last time also visible wavelengths, particularly green and blue, have been proposed for oral surgery, thanks to their great absorption in biological tissues [11-13].

Materials and methods

Case Report 1: Lingual frenectomy performed by Diode 808nm laser.

ST, a 17-year-old girl, was sent to our clinics by a physiotherapist who was taking care of her for a spinal column pain. Recently in fact, several Authors have described a relation between ankyloglossia and postural diseases and lingual frenectomy has

been proposed to improve physiotherapy treatment [14]. Due to physical examination had showed an abnormal insertion of the lingual frenum, with a 2nd class ankyloglossia of the Kotlow classification (**Fig. 1**), it was decided for a frenectomy by an 808nm diode laser (LaseMAr 800, Eufoton, Trieste, Italy).

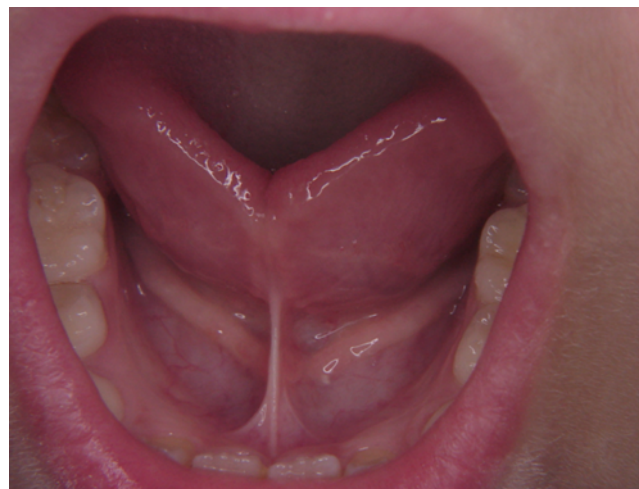

Fig. 1. Abnormal insertion of lingual frenum (Class 2nd of Kotlow classification)

The intervention had a duration of 145 sec, anaesthetics injection and sutures were not requested, and only a topic cream EMLA (AstraZeneca AB, Sodertalje, Sweden) was applied on the mucosa for five minutes before laser irradiation for pain controlling. (**Fig. 2**)

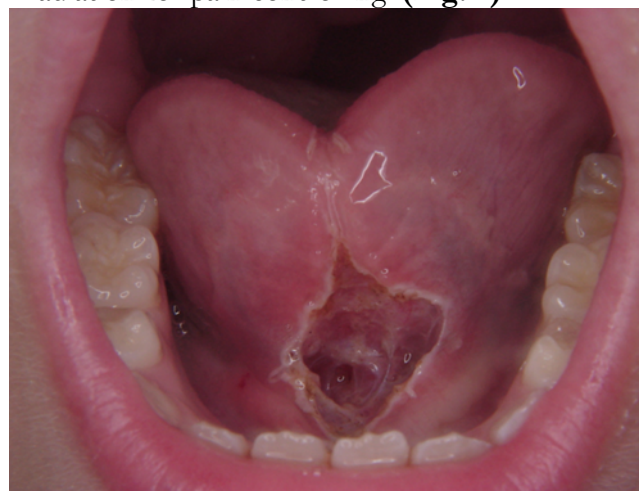


Fig. 2. Surgical area after intervention

Laser was used in contact mode (320 μ m diameter fiber) with an output power of 3W CW (continuous mode).

Subsequently, it was used an “at home” device (B-Cure, Israel) for 10 min photobiomodulation; this device was also given to patient for domestic use in the next week.

Just after intervention, it was noticed that the tongue was able to protrude over the lower lip and the patient was instructed to repeat this exercise also in the postoperative days, in order to avoid the risk of relapse. Follow-up was without complications and, after two weeks healing process was completed. (Fig. 3-4)

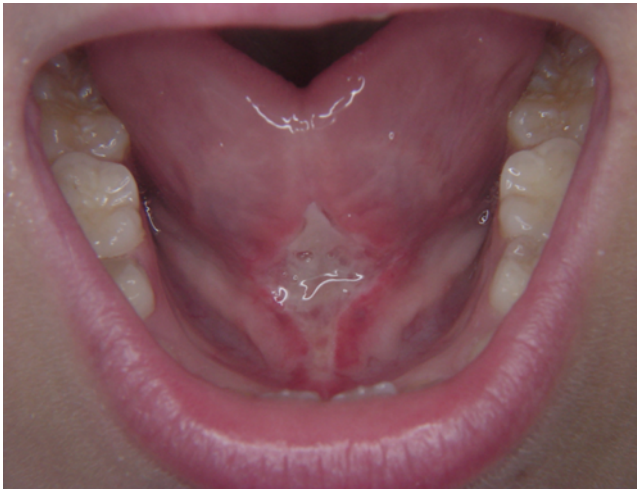

Fig. 3. Partial healing process one week after with fibrine deposition

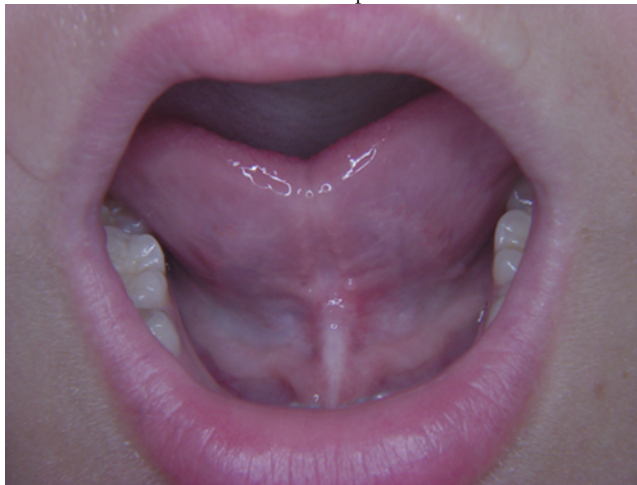

Fig. 4. Complete healing two weeks after

Case Report 2: Upper vestibular frenectomy performed by KTP laser.

PP, a 13-year-old boy, was sent to our clinics by his orthodontist who had suggested to cut the

abnormally inserted upper vestibular frenum before starting the orthodontic treatment. (Fig. 5)

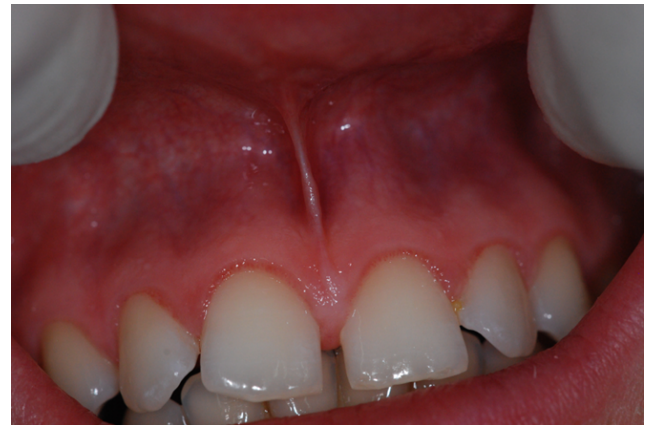

Fig. 5. Clinical examination: abnormal insertion of the upper vestibular frenum

After applying topic anesthetic in the surgical area (AstraZeneca AB, Sodertalje, Sweden) (Fig. 6), frenectomy was performed by KTP laser, emitting at 532 nm (LaseMar 500, Eufoton, Trieste, Italy) in the visible portion of the spectrum, with green light (Figg. 7-8). The optic fiber, used in contact mode, had a diameter of 320 μm and the output power of 3W CW (continuous mode) was used.

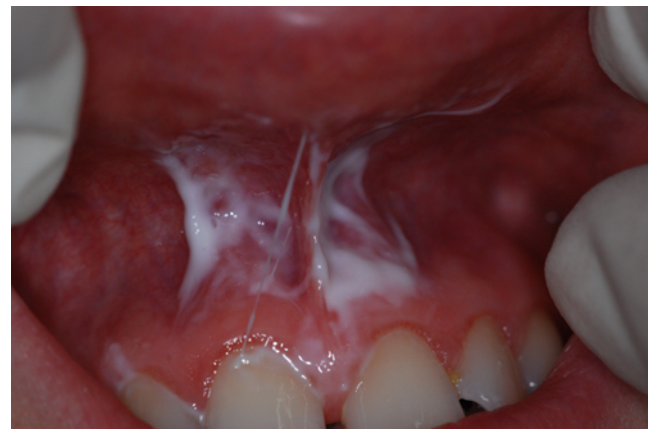

Fig. 6. Topical anaesthetics applied to the mucosa

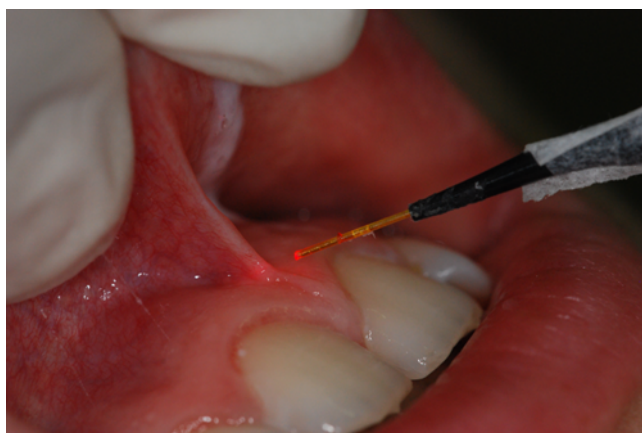

Fig. 7. 320µm fiber before irradiation

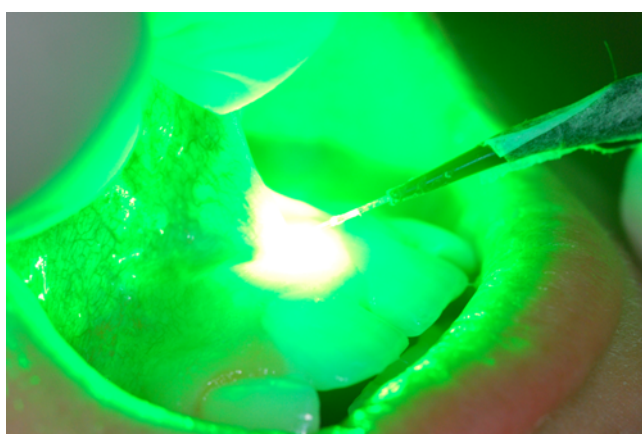


Fig. 8. 320µm fiber during KTP laser irradiation

The intervention had a duration of 110 sec, sutures were not applied due to the bleeding absence and 10 min of photobiomodulation were performed by “at home” device (B-Cure, Israel) just after KTP laser irradiation and also in the next week. **(Fig. 9)**

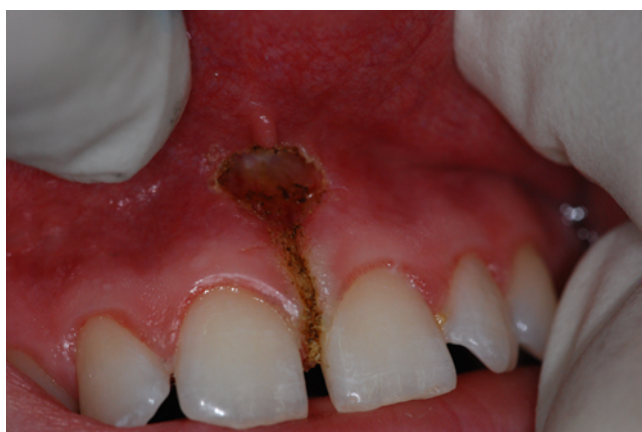

Fig. 9. Surgical area after intervention

Healing process was completed after ten days without any sort of problems. **(Fig. 10)**

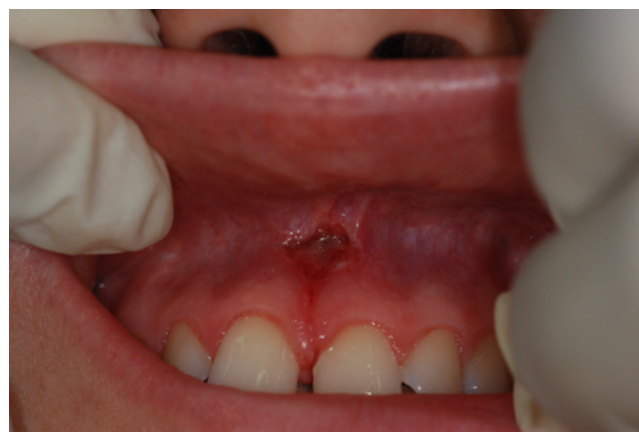

Fig. 10. Not complete healing process a week after

Case Report 3: Lower vestibular frenectomy performed by 445nm diode laser.

RM, an 18-year-old girl, came to our clinics because she had noticed an important gingival recession on the central lower incisors.

Clinical observation revealed an abnormal insertion of the frenum and so it was decided for its ablation by means of a laser device. **(Fig. 11)**

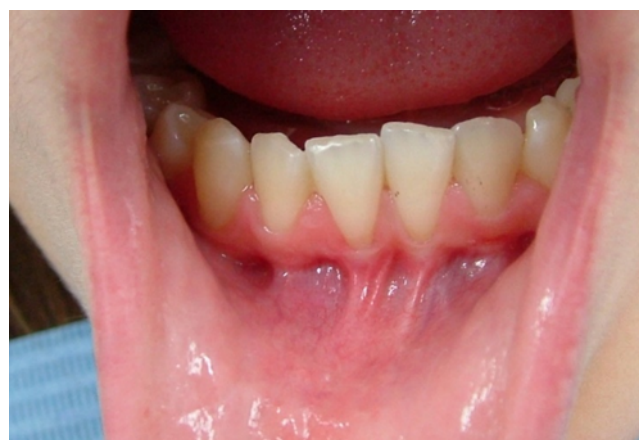

Fig. 11. Abnormal insertion of lower vestibular frenum associated to gingival recession of lower incisors

The surgical intervention was performed by a 445nm diode laser (Ermes, Gardalaser, Verona, Italy) emitting in the blue portion of the electromagnetic spectrum with an output power of 1W in CW and a 320 µm fiber diameter. Due to the low energy used and the great absorption of this

wavelength in the tissue no anaesthetics was needed and the irradiation time was very short (75 sec) (**Fig. 12**).

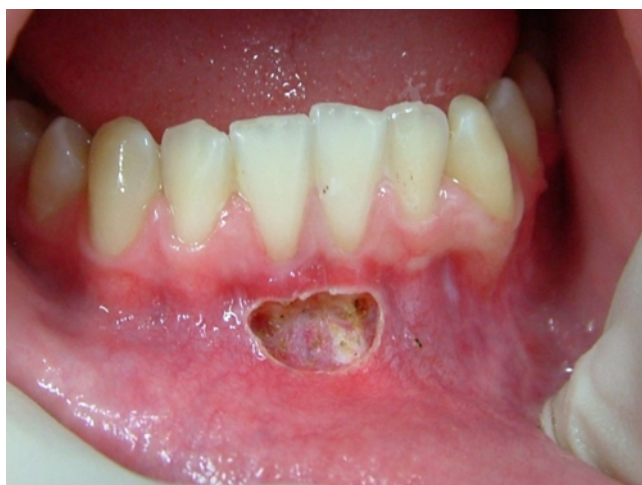

Fig. 12. Surgical site after intervention

Just after the blue laser irradiation, it was used an “at home” device (B-Cure, Israel) for 10 min photobiomodulation; this device was also given to patient for domestic use in the next week. The healing process was completed in a week. (**Fig. 13-14**)

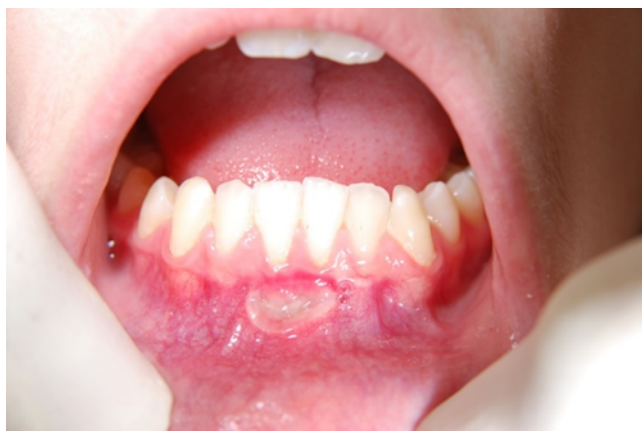

Fig. 13. Healing process three days after with fibrine deposition

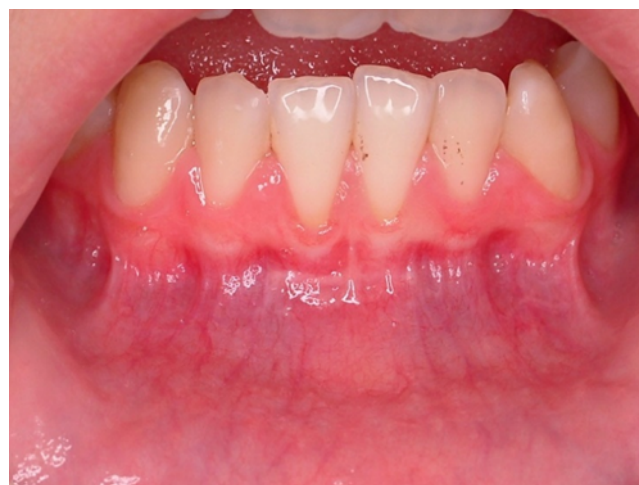

Fig. 14. Complete healing one week after

Discussion

Frenectomy is one of the minor oral surgical interventions where are more evident the advantages given by laser technology.

In fact, a good compliance of patients, due to the possibility to generally eliminate pain and discomfort without anesthetic injection as well as to avoid the use of sutures, associated to the short duration of intervention, make this approach very interesting in pediatric and “special need” patients [15].

Moreover, the possibility to move tongue and lips just after intervention, as well as in the next days as suggested to patients, results very effective in relapse avoiding.

Regarding the choice of the proper laser, in these last years a great attention has been focused in the advantages given by visible wavelengths, particularly blue light.

In fact, its great absorption in haemoglobin (**Fig. 15**) makes possible to perform a very effective ablation with a very low energy, this resulting in pain absence, faster healing process and better patient compliance [16].

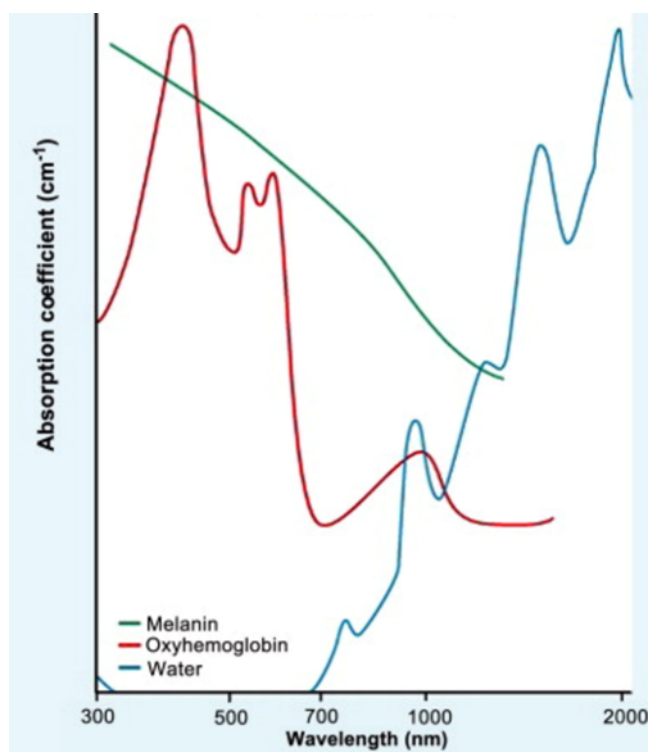


Fig. 15. Absorption of different chromophores by different wavelengths

An important aspect is related with the correct instructions to patients, seeing as laser surgery is very different from conventional, even in the follow-up.

Patient must be informed that, due to sutures are not used, the healing process is reached by the fibrine apposition and so, the presence of a yellow-brown aspect of the lesion in the days after intervention, must not be attributed to an infection but to a regular healing process.

Moreover, it must be informed to avoid brushing in this area as well as not to assume acid, salted and spicy food.

Finally, we must underline the great help to improve comfort in the follow-up given by photobio-modulation [17] both with traditional devices and with “at home” appliances able to be self-administered by patients themselves.

Conclusion

Laser technology may give several advantages in surgical frenectomies, particularly by using short visible wavelengths and associating photobio-modulation after surgery and in the follow-up.

References

- [1] Barek S, Adam O, Motsch JF. Large band spectral analysis and harmful risks of dental turbines. *Clin Oral Investig.* 1999 Mar; 3(1): pp. 49-54. doi: 10.1007/s007840050078. PMID: 10522193.
- [2] Giovannacci I, Meleti M, Merigo E, Mergoni G, Fornaini C, Manfredi M, Bonanini M, Vescovi P. Erratum to: Advantages of new technologies in oral mucosal surgery: an intraoperative comparison among Nd:YAG laser, quantum molecular resonance scalpel, and cold blade. *Lasers Med Sci.* 2015 Sep; 30(7): 1911. doi: 10.1007/s10103-015-1793-7. Erratum for: *Lasers Med Sci.* 2015 Sep; 30(7): 1903-10. PMID: 26290011.
- [3] Giovannacci I, Mergoni G, Meleti M, Merigo E, Fornaini C, Manfredi M, Bonanini M, Vescovi P. Postoperative discomfort in oral soft tissue surgery: a comparative perspective evaluation of Nd:YAG Laser, quantum molecular resonance scalpel and cold blade. *Minerva Stomatol.* 2015 Feb; 64(1): pp. 9-20. English, Italian. PMID: 25660590.
- [4] Fornaini C, Rocca JP, Bertrand MF, Merigo E, Nammour S, Vescovi P. Nd:YAG and diode laser in the surgical management of soft tissues related to orthodontic treatment. *Photomed Laser Surg.* 2007 Oct; 25(5): pp. 381-92.
- [5] Kotlow LA. Ankyloglossia (tongue-tie): a diagnostic and treatment quandary. *Quintessence Int.* 1999 Apr; 30(4): pp. 259-62.
- [6] Chaubal TV, Dixit MB. Ankyloglossia and its management. *J Indian Soc Periodontol.* 2011 Jul; 15(3): pp. 270-2.
- [7] Gracco A, Tracey S, Lombardo L, Siciliani G. Soft tissue laser in orthodontics. *Prog Orthod.* 2011; 12(1): pp. 66-72.
- [8] Edwards J.G.B. The diastema, the frenum, the frenectomy: a clinical study. *Am J Orthod.* 1977 May; 71(5): pp. 489-508.
- [9] Fornaini C, Merigo E, Vescovi P, Lagori G, Rocca J. Use of laser in orthodontics: applications and perspectives. *Laser Ther.* 2013; 22(2): pp. 115-24. doi: 10.3136/islm.22.115. Epub 2013 Mar 31. PMID: 24155556; PMCID: PMC3806063.
- [10] Bethaz N, Romano F, Ferrarotti F, Mariani GM, Aimetti M. A mucogingival technique for the treatment of multiple recession defects in the mandibular anterior region: a case series with a 2-year

- follow-up. *Int J Periodontics Restorative Dent.* 2014 May-Jun; 34(3): pp. 345-52. doi: 10.11607/prd.1920. PMID: 24804285.
- [11] Fornaini C, Sozzi M, Merigo E, Pasotti P, Selli S, Cucinotta A, Supercontinuum source in the investigation of laser-tissue interactions: “*ex vivo*” study. *Journal of Biomedicine*, 2017; 2(1): pp. 12-19. doi: 10.7150/jbm.17059
- [12] Fornaini C, Rocca JP, Merigo E, Meleti M, Manfredi M, Nammour S, Vescovi P. Low energy KTP laser in oral soft tissue surgery: A 52 patient’s clinical study. *Med Oral Patol Oral Cir Bucal.* 2012 Mar 1; 17(2): e287-91. doi: 10.4317/medoral.17428. PMID: 22143694; PMCID: PMC3448313.
- [13] Fornaini C, Merigo E, Rocca JP, Lagori G, Raybaud H, Selli S, Cucinotta A. 450 nm Blue Laser and Oral Surgery: Preliminary *ex vivo* Study. *J Contemp Dent Pract.* 2016 Oct 1; 17(10): pp. 795-800. doi: 10.5005/jp-journals-10024-1933. PMID: 27794148.
- [14] Pelosi A, *Interferenze Orali nelle Sindromi Cranio-Mandibolo-Cervicali e Posturali.* Castello Editore, 2008.
- [15] Merigo E, Fornaini C, Clini F, Fontana M, Cella L, Oppici A. Er:YAG laser dentistry in special needs patients. *Laser Ther.* 2015 Oct 2; 24(3): pp. 189-93. doi: 10.5978/islm.15-CR-02. PMID: 26557733; PMCID: PMC4639676.
- [16] Fornaini C, Fekrazad R, Rocca JP, Zhang S, Merigo E. Use of Blue and Blue-Violet Lasers in Dentistry: A Narrative Review. *J Lasers Med Sci.* 2021 Jul 4; 12: e31. doi: 10.34172/jlms.2021.31. PMID: 34733754; PMCID: PMC8558710.
- [17] Merigo E, Rocca JP, Pinheiro ALB, Fornaini C. Photobiomodulation Therapy in Oral Medicine: A Guide for the Practitioner with Focus on New

Possible Protocols. *Photobiomodul Photomed Laser Surg.* 2019 Nov; 37(11): pp. 669-680. doi: 10.1089/photob.2019.4624. E-pub 2019 Oct 7. PMID: 31589560.

Cite: Jean-Paul Rocca, Nathalie Brulat-Bouchard, Christine Voha, Hélène Raybaud, Caaroline Bertrand, Carlo Fornaini.
Use of laser in oral frenectomies: a case report series.
Laser Ther. Vol. 29 N.2 - June 2022, pagg.: 100-106.
DOI: 10.26352/GJ06F5003-June2022