

Dual laser circumcision: a novel technique to improve traditional surgery

Piero Ronchi¹, Simone Scarcella², Stefano Manno³, Valerio Beatrici², Lucio Dell'Atti^{4*}

¹Department of Urology, University Hospital "Ospedali Riuniti", Ancona, Italy

²Division of Urology, Azienda Ospedaliera Ospedali Riuniti Marche Nord, Pesaro, Italy

³Urology Unit, "Pugliese-Ciaccio" Hospital, Catanzaro, Italy

^{4*}Department of Quality, Risk Management and Technological Innovation in Healthcare Organization, University Hospital "Ospedali Riuniti", Ancona, Italy

ABSTRACT

Circumcision represents one of the oldest and routinely performed urological surgery. It implies the exeresis of the prepuce due to ethnic, religious and medical reasons. Different authors reported straightforward advantages of this procedure including increased penile hygiene, reduction of penile cancer risks and lower rates of urinary tract infections. Circumcision can be easily performed and reproduced according to different techniques. Nowadays, different types of lasers have been developed and this technology is gaining consensus in the urological community. Aim of this article is to describe our surgical technique for laser circumcision with the Lasemar Eufuton 1500, clarifying the surgical steps and the benefits of this technology.

Key words: Circumcision, Laser, Phimosis, Paraphimosis, Technological Innovations, Diode Laser

Introduction

Circumcision represents one of the oldest urological surgeries and it has been routinely performed since the Sumerian era.¹ It implies the exeresis of the prepuce, the skin covering the penile glans, and it can be performed for ethnic, religious and medical reasons. Major surgical indications are: paraphimosis, phimosis, posthitis, recurrent balanoposthitis/balanitis, lichen sclera-atrophicus and certain infectious diseases of the genitalia². There

are no reported specific contraindications to circumcision, however patients with active infection, suspected penile carcinoma or anatomic genitalia malformations should be further investigated prior to surgery. Different authors reported, within the scientific literature, straightforward advantages of this procedure such as increased penile hygiene, reduction of penile cancer risks and lower rates of urinary tract infections. Circumcision can be easily performed and reproduced according to different techniques. Fabrice D'Acquapendente³ in 1666,

*Running title:

Dual Laser Circumcision: novel technique

Corresponding Author:

Lucio Dell'Atti

Department of Quality, Risk Management and Technological Innovation in Healthcare Organization, University Hospital "Ospedali Riuniti" 71 Conca Street 60126 Ancona – Italy

Mail: dellatti@hotmail.com

Tel: +390715966523

firstly proposed a procedure based on a circular incision while Celse *et al.*,⁴ in 1754 suggested a longitudinal approach. Moreover, Bell and Ricord, respectively in 1796 and 1838, produced new surgical tools to ease the procedure.^{5,6}

Maiman developed the laser technology in 1959 and, since then, its application in medical surgery grew exponentially, due to its capacity to vaporize and sharply cut tissues. Nowadays, different types of lasers have been developed and this technology, once applied only to treatment of common skin diseases and aesthetic dermatology, is gaining consensus in the urological community.⁷

Aim of this article is to describe our surgical technique for laser circumcision with the LASEmaR® Eufoton® Mini DUAL 980/1470, clarifying the surgical steps and the benefits of this technology.

Material and Methods

LASEmaR® Eufoton® Mini DUAL 980/1470

LASEmaR® Mini DUAL 980-1470 (Eufoton® S.r.l.) (**Fig. 1**) is a new, fifth generation high power Diode portable laser with a power capacity output between 7-12 Watts and a dual working wavelength ranging from 980nm to 1470nm, with both pulsed or continuous energy transmission settings available.



Fig. 1. LASEmaR® Mini DUAL 980-1470 (Eufoton® S.r.l.)

Thanks to these technical specifics, its use has been already validated in different soft tissue surgical procedures (aesthetic medicine, plastic, gynaecology, general, proctological and endovenous phlebological surgery).⁸⁻¹¹ As consequence of its specific working wavelength (**Fig. 2**) it is a fast and efficient

laser for cutaneous incisions, allowing an atraumatic haemostasis, skin tightening and contouring with improved fractional rejuvenation of the skin.¹¹

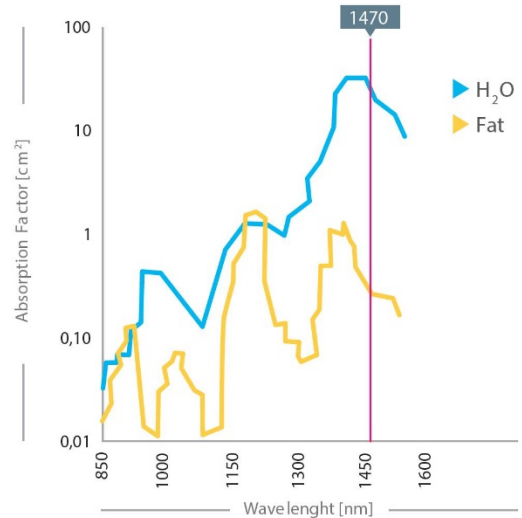


Fig. 2. Thanks to the high-water absorption, it allows a precise hemostasis, applying lower energetic levels LEED (Linear Endovenous Energy Density)

Moreover, is known as the present gold standard for the EVLA (Endovenous Laser Ablation) in the outpatient elimination of saphenous reflux thanks to the DPC (Dynamic Pulse Control), that allows a selective photocoagulation of water and fat, permitting a better endovenous occlusion at the lowest energetic levels LEED (Linear Endovenous Energy Density), and reduced thermal damages to neighbouring tissues⁸. In Gynaecology, due to the development of a specific Ladylift protocol it allows a safe treatment of vaginal atrophy and stress urinary incontinence, improving the tone of the vaginal walls and accelerating the production and the remodelling of mucosa's collagen.^{9,10}

The machine is extremely compact, multifunctional and enriched by numerous headpieces and pre-set protocols making the laser immediately usable for different specialistic treatments. For circumcisions, we use the surgical handpiece (**Fig. 3**), designed to improve ergonomics and dexterity.

It is a pen-like device providing a natural scalpel-like feel, equipped with a visible aiming beam that permits pinpoint accuracy, reducing damages to surrounding tissues during the procedure.

The device is both CE marked and FDA approved.




Fig. 3. surgical handpiece, designed to improve ergonomics and dexterity, equipped with a visible aiming beam that permits pinpoint accuracy, reducing damages to surrounding tissues during the procedure

Surgical Technique description

Informed consent should always be acquired providing the patient with detailed knowledge of the procedure ahead of time. Specifically, all information regarding possible complications such as bleeding, infection, hematoma formation, poor cosmetic results and change in sensation during intercourse should be given. The patient should also be enlightened those erections, occurring in the post-operative setting, could cause pain and disruption of the suture line requiring re-intervention. Full recovery generally requires between four to six weeks of abstinence from both genital stimulation and intercourse. The procedure can be performed in the outpatient setting or after hospital admission, according to patients' comorbidities and preferences. Preparation of the surgical site includes a thorough surgical scrub of the genital area with povidone-iodine preparation. Shaving and clipping of the pubic hair should be avoided to minimize the possibility of infection. Sterile draping of the area should be used to identify the surgical field. Subsequent adequate local or regional anaesthesia should be administered. We usually perform a dorsal penile nerve block with or without a circumferential ring penile block according to patient's response to the first injection. The first step of the procedure requires the retraction of the prepuce over the glans penis with frenulum exposure and incision (**Fig. 4**).

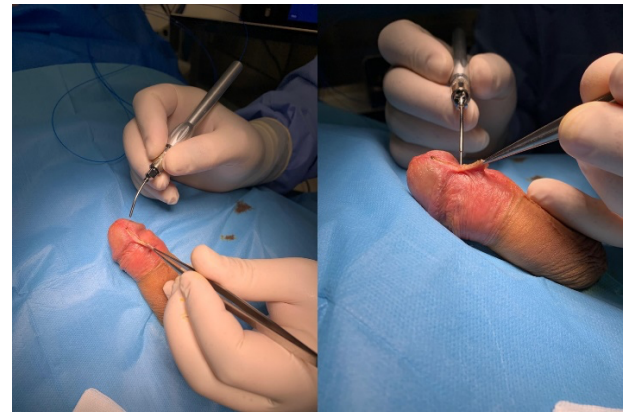


Fig. 4. frenulum exposure and incision

Then a circumferential cut is made around the shaft as far back as the scar line is to be placed, usually few millimetres distal to the corona (**Fig. 5**).

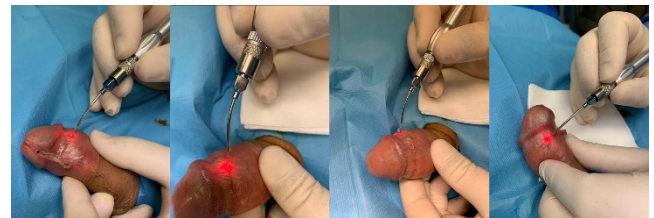


Fig. 5. circumferential cut around the shaft few millimeters distal to the corona

A second circumferential incision is made around the shaft according to the prepuce tissue that has to be removed (**Fig. 6**).

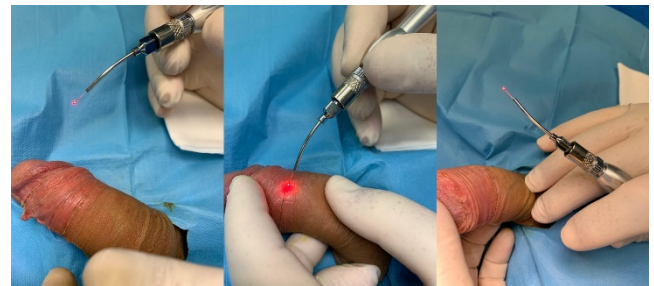

Fig. 6. second circumferential incision

A longitudinal cut is then made between the two previous circumferential ones (**Fig. 7**) and the excisional procedure is completed with the progressive bloodless incision and stripping of the rebounding prepuce (**Fig. 8**).

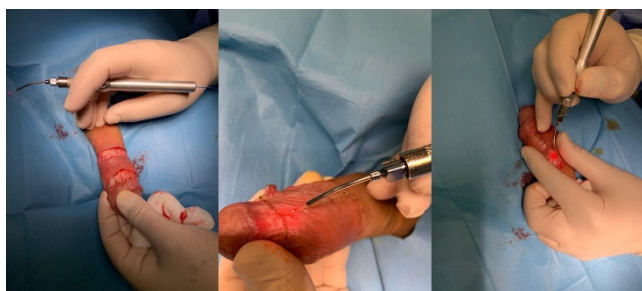


Fig. 7. a longitudinal cut is made between the two previous circumferential ones

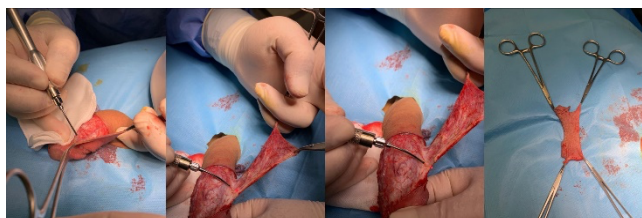

Fig. 8. the excisional procedure is completed with the progressive incision and stripping of the rebounding prepuce.

The free raw edges are re-approximated with four initial quadrant sutures placed on the dorsum, both sides and frenulum with the remaining foreskin sutured through simple interrupted sutures every four to seven mm intervals (**Fig. 9**).

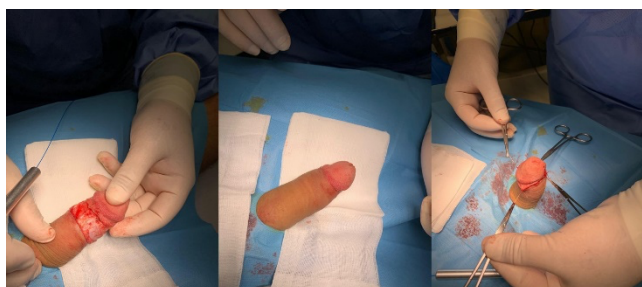


Fig. 9. the remaining foreskin sutured through simple interrupted sutures every four to seven mm intervals

The final appearance of the penile shaft is depicted in **Fig. 10**.

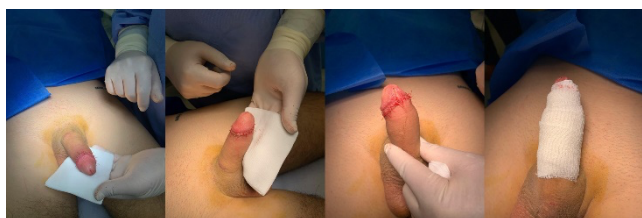

Fig. 10. finale appearance with compressive sterile dressing

While many surgeons use no dressing at all following the procedure, we usually apply a petroleum sterile jelly gauze wrapped circumferentially around the sutured area, followed by sterile gauze and lightly closed with self-adherent stretch gauze. This dressing is removed within 24 to 48 hours after surgery with no need of further dressing; the patient is then advised to gently wash the wound twice daily for the next seven days. After one month from the procedure the patient should be scheduled for a follow up consultation to verify the complete healing of the surgical site.

Discussion

Circumcision is one of the most common urological procedures, routinely performed in different countries for medical, religious and cultural purposes. The benefits include both the reduction of urinary tract infections and sexually transmitted diseases, balanitis, posthitis, phimosis and paraphimosis prevention. In addition, when performed by trained physicians, it is a safe and reproducible surgery with low complication rates.¹² Even though considered a simple procedure, some risk of complications needs to be taken into account. The most common one is bleeding, with an incidence varying between 0.1% to 3.1%, which can be easily controlled by ligation or electrocoagulation.¹³ Other rarely reported complications are local edema and tenderness, hematoma, infection, wound dehiscence and scarring.¹⁴ Within the scientific literature, different conventional techniques have been described including the dorsal slit, the sleeve and the guillotine approaches.¹⁵ During recent years, technological advances such as CO₂ or YAG lasers have been proposed alternatively to the standard scalpel.^{16,17} Moreover, various non-invasive circumcision devices have been increasingly used due to reduced recovery periods, faster operative times and shorter learning curves.¹⁸ The CO₂ laser was used for the first time in this field in 1964 by Patel and collaborators, reporting promising outcomes thanks to its high-water absorption, precise incision, excision and thermo-coagulation of small blood vessels with both improved haemostasis and a dry

surgical field.¹⁹ Gorgulu *et al.*,²⁰ demonstrated the association between the adoption of CO₂ laser and shorter operative time thus reducing bleeding complications and post-procedural pain, when compared with the traditional Guillotine technique. Xu *et al.*,²¹ reported similar outcomes regarding the safety and efficacy of a modified CO₂ laser circumcision approach compared with the standard dorsal slit-sleeve one. Other Authors²² confirmed these findings, publishing their personal experience in various case series.

The Holmium YAG laser has been proposed as a substitute technology for circumcision thanks to a molecular absorption of water particles around 2140 nm with a penetration depth of 0.4 mm, allowing both incision and coagulation, providing shorter operative time, less postoperative pain, less blood loss and fewer complications compared to traditional techniques.¹⁶

A compelling development in this field could be the application of diode laser to further improve laser circumcision outcomes. To the best of our knowledge, we present the first study describing the efficacy and safety of a circumcision technique using diode laser. Thanks to this technology, it is possible to incise and obtain an optimal haemostasis through the accurate cauterization of small vessels. Moreover, due to its beneficial physical properties, it provides enhanced precision in both cutting and sealing surfaces with reduced blood losses and less postoperative pain. This is of paramount importance considering the potential risks for sub-clinical penile injuries caused by an excessive use of mono-polar electrocoagulation. Tuncer *et al.*, described electrical burns, penile tissue damages and necrosis contributing to both erectile tissue dysfunction and irregular wound edges with poor cosmetic outcomes due to conventional mono-polar electrocoagulation.²³ For these reasons, they suggested to perform haemostasis with bipolar or laser technologies, as lower power (W) settings, are associated with reduced thermal transmission to surrounding tissues. Furthermore, diode laser could provide improved cosmetic appearances inducing both wound healing and skin remodelling, while maintaining the advantages of cutting and coagulating at the same time. Moreover, the ergonomic handpiece can be held close to tissues

increasing both the stability of the surgeon's hands and treatment precision.

This work represents the first application of diode laser technology to safely and effectively perform circumcisions. It is a personal modified technique of a surgeon (P.R.) with more than 20 years' experience with both traditional and laser circumcision techniques. Further prospective studies and randomized trials are advocated to both confirm the promising results of this new approach and compare the outcomes with traditional procedures.

Conclusions

We present for the first time a personal modified technique with Diode laser for circumcisions. This laser allows a precise cut and cauterization of surgical margins at the same time, reducing wound irritation with a better cosmetic appearance.

Moreover, the diode laser technology allows an accurate haemostasis implementing the surgical view during the procedure with a dry surgical field.

References

- [1] Massry, S.G. History of circumcision: a religious obligation or a medical necessity. *J. Nephrol*, 2011; 24, S100-S102.
- [2] Hirji H, Charlton R, Sarmah S. Male circumcision: a review of the evidence. *JMHG*, 2005; 2: pp. 21-30.
- [3] Fabrice d'Acquapendente: *Oeuvres chirurgicales*. Lyon, Huguetau, 1666, pp. 712-714.
- [4] Celse AC: *Traité de la médecine*. Paris, Vincent, 1754, livre 7, sec 25.
- [5] Bell B: *Cours complet de chirurgie théorique et pratique*. Paris, Barrois, 1796, vol 1, pp. 300-310.
- [6] Ricord Ph: *Traité pratique des maladies vénériennes*. Paris, Baillière, 1838: pp. 105-109.
- [7] Morris BJ, Krieger JN. Penile Inflammatory Skin Disorders and the Preventive Role of Circumcision. *Int J Prev. Med*, 2017; 8: 32.
- [8] Zhang X, Wang X, Gao C, Qin J, Zhao H, Li W, Lu X. A 1470-nm laser combined with foam sclerotherapy in day surgery: a better choice for lower limb varicose veins. *Lasers Med Sci*, 2018; 33(7): pp. 1505-1511.
- [9] Dodero D, Frascani F, Angelucci M, Bernabei G, Merlo E, *et al.*, Histological Modifications of Postmenopausal Vaginal Mucosa after Regenerative Solid State Laser Treatment: A Multicenter Study. *Int J Womens Health Wellness*, 2019; 5: 099.

- [10] Dodero D, Frascani F, Angelucci M, Bernabei G, Merlo E, *et al.*, Solid State Vaginal Laser for the Treatment of Genitourinary Syndrome of Menopause: A Preliminar Report. *Open Journal of Obstetrics and Gynaecology*, 2018; 8:201.
- [11] Li K, Nicoli F, Xi WJ, Zhang Z, Cui C, Al-Mousawi A, Balzani A, Tong Y, Zhang Y. The 1470 nm diode laser with an intralesional fiber device: a proposed solution for the treatment of inflamed and infected keloids. *Burns Trauma*, 2019; 15; 7:5.
- [12] Tobian AA, Gray RH. The medical benefits of male circumcision. *JAMA*, 2011; 306: pp. 1479-1480.
- [13] Weiss HA, Larke N, Halperin D, Schenker I. Complications of circumcision in male neonates, infants and children: a systematic review. *BMC Urol*, 2010; 10:2.
- [14] Williams N, Kapila L. Complications of circumcision. *Br J Surg*, 1993; 80: pp. 1231-1236.
- [15] Hayashi Y, Kojima Y, Mizuno K, *et al.*, Prepuce: phimosis, paraphimosis, and circumcision. *ScientificWorldJournal*, 2011; 11: pp. 289-301.
- [16] Vaos G. Circumcision with the Nd:YAG laser contact technique compared with conventional surgery. *Photomed Laser Surg.*, 2004; 22: pp. 318-322.
- [17] Kaplan I. The CO₂ laser in clinical surgery-past, present and future. *Ann Acad. Med Singapore*, 1987;16: pp. 286-289.
- [18] InformedHealth.org [Internet]. What are the treatment options for phimosis? Cologne, Germany: Institute for Quality and Efficiency in Health Care (IQWiG); 2015 [Updated Oct 2018]. <https://www.ncbi.nlm.nih.gov/books/NBK326433/>
- [19] Sakkas, G., Karayannis, A., Karayannis, D., *et al.*, Laser treatment in urology: our experience with neodymium:YAG and carbon dioxide lasers. *Int. Urol. Nephrol*, 1995; 27, pp. 405-412.
- [20] Gorgulu T, Olgun A, Torun M, Kargi E. A fast, easy circumcision procedure combining a CO₂ laser and cyanoacrylate adhesive: a non-randomized comparative trial. *Int Braz J Urol*, 2016; 42(1): pp. 113-117.
- [21] Xu Y, Li F, Li Z, Guan W, Wu Y, Ouyang Y, Zhao Y, Liu C. A prospective, randomized controlled trial of circumcision in adult males using the CO₂ laser: modified technique compared with the conventional dorsal-slit technique. *Photomed Laser Surg*, 2013; 31(9): pp. 422-427.
- [22] Ronchi P, Manno S, Dell'Atti L. Technology Meets Tradition: CO₂ Laser Circumcision versus Conventional Surgical Technique. *Res Rep Urol*, 2020: pp. 255-260.
- [23] Tuncer I, Ozcakir-Tomruk C, Sencift K, *et al.*, Comparison of conventional surgery and CO₂ laser on intraoral soft tissue pathologies and evaluation of the collateral thermal damage. *Photomed Laser Surg*, 2010;28: pp. 75-79.

Cite: Piero Ronchi, Simone Scarcella, Stefano Manno, Valerio Beatrice, Lucio Dell'Atti.
Dual Laser Circumcision: a novel technique to improve traditional surgery. Laser Ther. Vol. 29 N.2 - June 2022, pagg.: 94-99.
DOI: 10.26352/GJ06F5002-June2022